



The endometrial expression level of estrogen- α and VEGF-A in female rats administered with a low dose of estrogen in early clomiphene citrate therapy

R. Landahur¹ , B. Santoso¹ , W. Widjiati² , E.M. Luqman² 

¹Department of Obstetrics and Gynaecology, Faculty of Medicine, ²Department of Veterinary Science, Faculty of Veterinary Medicine, University of Airlangga, Surabaya, Indonesia

Article information

Article history:

Received March 20, 2022

Accepted October 13, 2022

Available online December 24, 2022

Keywords:

Clomiphene

Estrogen receptor α

Endometrium

Reproductive health

VEGF-A

Correspondence:

E.M. Luqman

epy-m-l@fkh.unair.ac.id

Abstract

The study was conducted to determine the effect of low-dose estrogen in the early cycle of clomiphene citrate therapy on the expression of level estrogen receptor α (ER α) and VEGF-A in the endometrium. This study was an experimental study using 29 adult female rats aged 3 months with the body weight of 150-200 grams. The female rats were randomly allocated to be allocated randomly into 3 groups (C: placebo; T1: treated with clomiphene citrate (100 mg/kg BW, IP, single dose); T2: combination treatment with clomiphene citrate (100 mg/kg BW, IP, single dose) and estradiol valerate (15 pg/kg BW, IP, single dose). Uterine samples were examined for estrogen- α receptor expression and VEGF-A expression using immunohistochemistry. The results revealed a significant difference between the percentage of Estrogen- α in the C group compared with the T1 and T2 groups. Meanwhile, there was no significant difference between the T1 and T2 groups. The percentage of VEGF-A expression in group C was significantly different compared with T1 and T2. Meanwhile, there was no significant difference between the T1 and T2 groups. In conclusion, administration of a low dose of estradiol valerate in early clomiphene citrate therapy resulted in no significant effect on estrogen- α receptor expression and VEGF-A expression in the endometrium.

DOI: [10.33899/ijvs.2022.133333.2207](https://doi.org/10.33899/ijvs.2022.133333.2207), ©Authors, 2023, College of Veterinary Medicine, University of Mosul.

This is an open access article under the CC BY 4.0 license (<http://creativecommons.org/licenses/by/4.0/>).

Introduction

Clomiphene citrate is often the first choice in infertility cases caused by an anovulatory state and oligo ovulation, even empirically used for ovarian stimulation in regular ovulation cycles. The two main indications for using clomiphene citrate are ovulation induction in cases of anovulatory infertility and multi-follicular ovulation stimulation to increase ovulation in ovulating infertile, such as unexplained infertility (1). Clomiphene citrate is often used because of its easy administration method, relatively cheaper, relatively safe use, and high success rate for ovulation. Several studies have reported that clomiphene citrate, along with hCG, can be used to induce ovulation in

pre-pubertal (2-4). Endometrial growth failure is a sensitive stage in preparation for implantation because it causes desynchronization between the embryo and the readiness of the uterus for implantation. Preparation of the endometrium from the proliferation phase to the secretion phase is an essential step in achieving the receptive state required for implantation. The proliferative phase is associated with the growth of ovarian follicles and increased secretion of estrogen. As a result, there is reconstruction and growth of the endometrium. The estrogens, apart from causing an increase in the expression of estrogen receptors, also stimulate the expression of genes and receptors of several biochemical agents such as cytokines, lipids, and peptides that are present in the endometrium, including several

growth factors that are potent mitogens for growth (5). Endometrial growth depends on the ability to regenerate the capillary vascular tissue and the proliferation and differentiation of the endometrial lining. One of the angiogenic factors that have a significant role in vascular growth is VEGF. During the proliferative phase, estrogen stimulates VEGF synthesis. The response to exogenous steroid administration affects the proliferation and function of endometrial capillaries (5-7). Until now, no studies have been carried out using low doses of estrogen at the start of the cycle to suppress the anti-estrogen effect of the endometrium on clomiphene citrate therapy to increase therapeutic efficacy. This study was conducted with the administration of low doses of estrogen using estradiol valerate at the beginning of the cycle in therapy with clomiphene citrate, with the precaution that this does not affect the hypothalamic-pituitary-ovarian axis. It only acts locally on the endometrium, and early cycle estrogen administration aims to induce estrogen receptors and regulates gene expression for autocrine and paracrine factors in the endometrium before starting clomiphene citrate therapy.

This study aims to determine the effect of a low dose of estrogen in the early cycle of clomiphene citrate therapy on the expression of estrogen receptor (ER α) levels and VEGF-A in the endometrium of female's rats (*Rattus norvegicus*) aged 3 months.

Materials and methods

This experimental study used a randomized post-test-only control group design involving 29 female rats aged 3 months with a bodyweight of 150-200 grams. The rats were allocated randomly into 3 groups. The animal received a standard pellet diet and drank water freely; the room temperature was 23 \pm 2 $^{\circ}$ C, and there were twelve hrs of light/dark cycles during the experiment. Control group (C) is placebo / did not receive treatment. Groups (T1), rats received a single dose of clomiphene citrate 100 mg/kg body weight intraperitoneal, and groups (T2) received a single dose of a combination of clomiphene citrate (Serophene-Sanofi-Aventis U.S. LLC) 100 mg/kg body weight and a single dose of estradiol valerate (Hikma Pharmaceuticals USA Inc) 15 pg/kg body weight intraperitoneal in early proestrus (T2). The administration is done in a single dose. The rats were sacrificed at the metestrus stage, then the rats were dissected, cardiac blood was withdrawn, and endometrial preparation was performed.

Estrous stage determination

The rats were subjected to vaginal swabs utilizing a wet cotton bud inserted into the vagina while rotated, then smeared on the object glass. The object glass was fixed with 70% alcohol, dipped with Giemsa dye, and then washed and

dried. Finally, the slides were examined under a microscope to determine the stages of the estrous cycle (8).

Assessment of the estrogen level in blood

Blood in the early stages of proestrus and metestrus were taken, then allowed to clot, and centrifuged at 3000 rpm for 10 minutes at 4 $^{\circ}$ C to separate blood serum to be used by radio immune assay for assessment of estradiol levels.

Examination of estrogen- α receptor expression and VEGF-A by immunohistochemistry

After treatment, the rats were euthanized at the metestrus stage. Then the rats were dissected, blood was drawn intracardiac and uterine preparation was performed. The uteri were fixed in 10% formalin buffer, and histopathological endometrial tissue was prepared (9).

The sample part was immersed in methanol containing 3% diluted hydrogen peroxide. To inhibit nonspecific binding, Dako cytomation (reagent peroxidase blocking S200/30-2- Bio-Rad Laboratories, Inc. Indonesia) was applied to sample parts and then incubated at room temperature with primary antibodies toward Anti-Estrogen Receptor alpha (SP1) monoclonal antibodies (ab16660) Abcam Inc Cambridge, UK. (1: 300), and Anti-VEGFA (EP1176Y-C-terminal ab52917) AK, BK - monoclonal antibodies Abcam Inc Cambridge, UK. (1: 300). Then, all samples were incubated with biotin-labeled secondary antibodies (Trekki Universal Link-Biocare Medical USA) then incubated overnight using streptavidin-conjugated peroxidase (Trekavidin-HRP Label Biocare Medical USA) and DAB as chromogen (BioLegend, Inc. San Diego, California, United States), based on the manufacturer's instructions. These parts were calculated with hematoxylin, dehydration, and installed.

Expression of Estrogen- α receptor and VEGF-A measurements were calculated based on the number of epithelial cells expressing estrogen- α receptor and VEGF-A in the vaginal wall tissue determined by calculating the mean number of vaginal wall cells that react positively to monoclonal antibodies seen under a microscope with 600x magnification in 10 fields of view using the Olympus DP12 Digital Camera (10).

Semi-quantitative scale index Remelle scale is the result of multiplying the positive cell percentage score with the color reaction intensity score (11). The positive cell percentage score: Score 0: No positive cells; Score 1: Positive cells <10%; Score 2: Positive cells between 11% and 50%; Score 3: Positive cells between 51% and 80%; and Score 4: Positive cells over than 80%. And the color reaction intensity score within: Score 0: no color reaction; Score 1: Low color intensity; Score 2: Medium color intensity; and Score 3: Strong color intensity.

Statistical analysis

Data were analyzed using the SPSS 24.0 software and first tested for normality using the Kolmogorov-Smirnov test. Furthermore, non-parametric data were verified using the Kruskal Wallis Test, then intervariable using Mann Whitney U Test to find the differentiation of each group, and $p \leq 0.05$ was considered statistically significant (12).

Results

The administration of low doses of estrogen using estradiol valerate in clomiphene citrate therapy has a different effect. The three groups resulted in the expression of estrogen- α and VEGF-A receptors in the endometrial tissue. According to the histopathological samples, estrogen receptor- α in the uterus sample expresses high positive expression in the Control group (C) and moderate expression on T1 and T2 group. Figure 1 and table 1 show the number of cells expressing estrogen- α receptors. The median value in the control group is 7.15, with an IQD of 1.35. Meanwhile, the median value of the T1 group was 3.0 with an IQD of 0.55, and the T2 group was 2.6 with an IQD of 0.65. The Kruskal Wallis Test was analyzed to see any differences between the three treatment groups. These results indicate a significant difference between the three groups ($P < 0.01$).

Advanced statistical tests between groups used the Mann-Whitney U test because the data were ordinal and

normally distributed. Based on the results of the Mann-Whitney U test, there was a significant difference between the percentage of estrogen- α expression in the control group (C) with the T1 group ($P=0.000$; $\alpha < 0.01$) and T2 ($P=0.000$; $\alpha < 0.01$). Meanwhile, there was no significant difference between the T1 and T2 groups ($P=0.243$; $\alpha > 0.05$) (Figure 2 and Table 1).

VEGF-A in the endometrial tissue sample expresses high expression in the control group (C) and moderate expression in the T1 and T2 groups (Figure 3). Figure 4 and Table 2 show the number of cells expressing VEGF-A. The median value in the control group is 17.6, with an IQD of 3.5. In the T1 group, the median score was 8.6 with an IQD of 2.15, and the T2 group median was 7.05 with an IQD of 1.31. Statistical tests using the Kruskal Wallis Test showed significant differences between the three treatment groups ($P=0.000$; $\alpha < 0.01$).

Analysis using Mann Whitney U test showed a significant difference between the percentage of VEGF-A expression in the control group and T1 group ($P=0.000$; $\alpha < 0.01$) and between the control group with T2 group ($P=0.000$; $\alpha < 0.01$). Meanwhile, there was no significant difference between the T1 and T2 group ($P=0.218$; $\alpha > 0.05$). Based on the correlation test between the estrogen- α receptor variable and the VEGF-A variable using Spearman Correlation Test, there is a significant positive correlation of 64.1% ($P=0.2641$; $\alpha < 0.01$) (Figure 4).

Table 1: Mean and SD of estrogen- α receptor expression in endometrium

Group	Estrogen- α Receptor Expression							
	n	Mean	SD	Median	IQD	Min.	Max.	p
C	10	7.39	1.54	7.15	1.35	4.7	9.3	
T1	9	3.03	0.69	3.0	0.55	1.8	3.9	0.000*
T2	10	2.62	0.65	2.6	0.65	1.7	3.3	

note: (*) significant at 0,000; $p < 0.01$; SD: standard deviation; IQD: interquartile deviation; C: control group; T1: clomiphene citrate 100 mg/kg BW; T2: a combination of clomiphene citrate 100 mg/kg BW and estradiol valerate at a dose of 15 μ g/kg BW.

Table 2: Mean and SD of VEGF-A expression in endometrium

Group	VEGF-A Expression							
	n	Mean	SD	Median	IQD	Min.	Max.	p
C	10	18.11	3.44	17.6	3.5	13.5	22.6	
T1	10	8.63	2.06	8.6	2.15	5.5	11.7	0,000*
T2	10	7.63	1.92	7.05	1.31	5.8	11.3	

note: (*) significant at 0,000; $p < 0.01$; SD: standard deviation; IQD: interquartile deviation; C: control group; T1: clomiphene citrate 100 mg/kg BW; T2: a combination of clomiphene citrate 100 mg/kg BW and estradiol valerate at a dose of 15 μ g/kg BW.

Discussion

Clomiphene citrate administration in the treatment will affect estrogen in the form of a selective estrogen receptor modulator. Clomiphene acts as a competitive inhibitor to the estrogen receptor. Depending on the target tissue, the effect can be an agonist or an antagonist. Clomiphene citrate

consists of two geometric isomers: Zuclomiphene 38% in the -cis array and Enclomiphene (62%) on -trans. Enclomiphene is more dominant in the ovulation induction process, and both work effectively on the uterus. The enclomiphene has a short half-life, while zuclomiphene has a longer half-life. Regarding estrogenic activity, zuclomiphene has more significant estrogenic activity than enclomiphene (13).

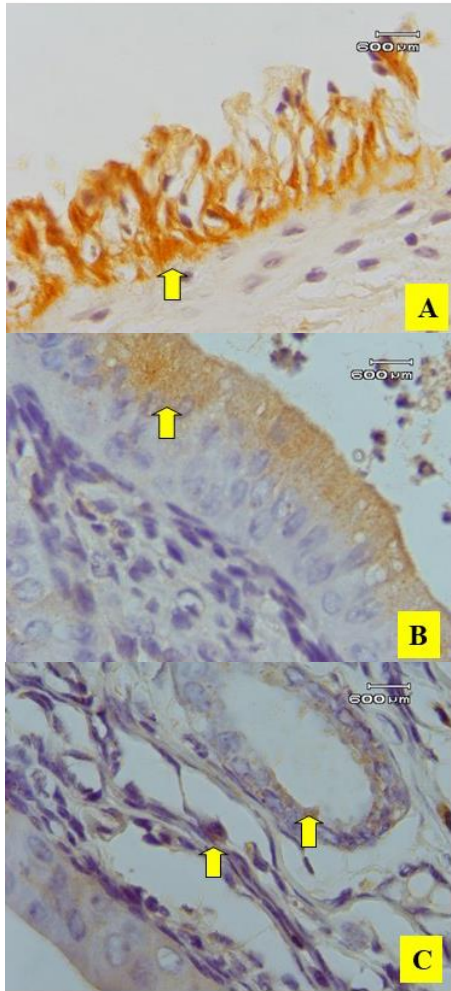


Figure 1: Immunohistochemical staining pattern of estrogen receptor- α in endometrium. Estrogen receptor- α expressed positive at cytoplasm in an endometrial tissue sample (yellow arrow). A: C Group (Control); B: T1 Group; C: T2 Group (scale bar = 60 μ m).

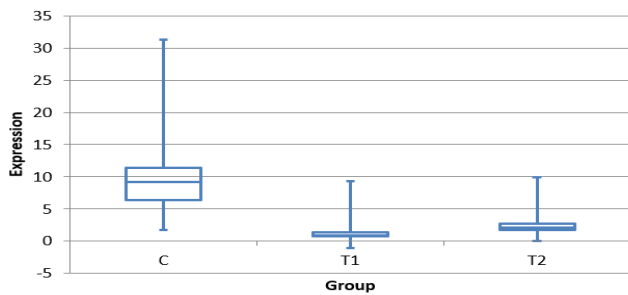


Figure 2 Schematic overview of endometrium's estrogen- α receptor in three examination groups (C: control group; T1: clomiphene citrate 100 mg/kg BW; T2: a combination of clomiphene citrate 100 mg/kg BW and estradiol valerate at a dose of 15 μ g/kg BW).

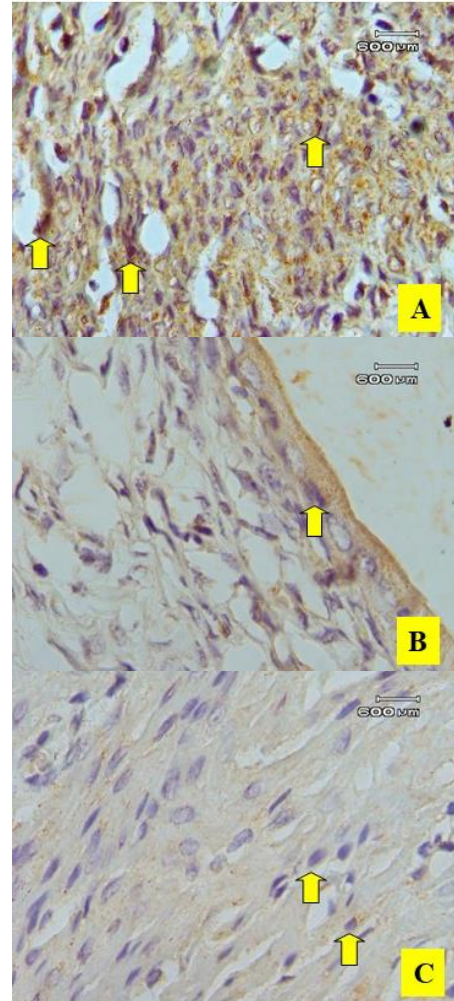


Figure 3 Immunohistochemical staining pattern of VEGF-A in endometrium. VEGF-A positive expressed at cytoplasm in an endometrial tissue sample (yellow arrow). A: C Group (Control); B: T1 Group; C: T2 Group (scale bar = 60 μ m).

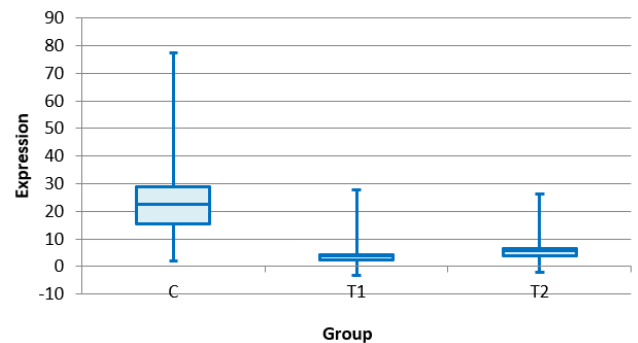


Figure 4: Schematic overview of endometrium's VEGF-A in three examination groups (C: control group; T1: clomiphene citrate 100 mg/kg BW; T2: a combination of clomiphene citrate 100 mg/kg BW and estradiol valerate at a dose of 15 μ g/kg BW).

With clomiphene administration, there was an increase in the concentration of follicle-stimulating hormone (FSH) and luteinizing hormone (LH) in plasma. When clomiphene is given to regular cycles, there is an increase in the pulsatile LH frequency (but not the amplitude), indicating an increase in the pulsatile gonadotropin-releasing hormone (GnRH) frequency. Enclomiphene acts as an anti-estrogenic in this case by blocking negative feedback from estradiol on the hypothalamic-pituitary axis, which causes an increase in LH and FSH. The chemical structure of clomiphene is similar to estrogen. It can bind to estrogen receptors in the nucleus. However, this clomiphene can bind to estrogen receptors for a long time. Clomiphene that binds to estrogen receptors in the hypothalamus causes the hypothalamus to pick up false signals about estrogen levels circulating in the blood so that estrogen levels are perceived to be lower than the actual level and stimulate the release of FSH and then stimulate a surge in LH that can cause ovulation (13,14).

Clomiphene administration causes an inhibitory effect on the transcription of the estrogen response element (ERE) gene activation of 17 β -estradiol (E2) and endometrial cell proliferation through inhibition of the steroid receptor coactivator-1 (SRC-1), which binds to the estrogen receptor. Clomiphene will occupy the ligands of estrogen receptors, but it also causes the number of estrogen receptors to decrease, thereby inhibiting the action of estrogen in the endometrium. This is linear with this study which explains why the number of estrogen receptor expressions in T1 and T2 treatment is lower than in the C group (15,16).

In addition, the expression of estrogen receptors between the T1 group given clomiphene and T2 given a combination of estradiol valerate and clomiphene was insignificant. This is linear with the study of (14), which reported that the level of estrogen in the single clomiphene group and the combination of clomiphene and estradiol were not significantly different. The addition of estradiol or estrogens valerate is less responsive to the endometrium. These results are also in line according to Elkind-Hirsch *et al.* (17). According to Elkind-Hirsch *et al.* (17), expression results, such as research, may be significant if examined during the proliferative phase. Taheripanah *et al.* (18) explained that combining clomiphene and valerate estrogen would increase the estrogenic effect only in blood plasma but had no significant effect on the endometrium. Therefore the expression of estrogen receptors in the clomiphene group was not significantly different from the clomiphene and estrogen combination group (14-19).

In line with the results of the estrogen receptor expression, the VEGF-A expression between the T1 group given clomiphene and T2 given the combination of estradiol valerate and clomiphene was not significant. This is because ER α mediates the increase in VEGF via E2. So the lower the expression of estrogen receptors, the lower the resulting VEGF-A expression. The results reinforce that estrogen receptor expression positively correlates with VEGF-A

expression. Clomiphene administration which inhibits the transcription of 17 β -estradiol (E₂) ERE gene transcription activation, also triggers inhibition of VEGF-A expression. Mueller (20) reported in their study that a single ERE variant associated with E2 induces transcription of the VEGF-A gene in endometrial cells. The increased expression of VEGF in the endometrium and vascular vessels is due to the effect of estradiol. Molecular evidence is reported by De Francesco *et al.* (21), which states that ER α mediates the increase in VEGF through E2. The presence of E2 induces the expression of ER α through the VEGF regulator, namely hypoxia-inducible factor-1 α (HIF-1 α). E2 signal transduction travels through the GPER / EGFR / ERK / c-fos pathway, increasing HIF-1 α expression and stimulating VEGF production (20-23). Administration of low-dose estrogen using estradiol valerate in the early cycle of clomiphene citrate therapy did not significantly affect estrogen- α receptor expression and VEGF-A expression in the endometrium.

Conclusion

Administration of a low dose of estradiol valerate in early clomiphene citrate therapy resulted in no significant effect on estrogen- α receptor expression and VEGF-A expression in the endometrium.

Acknowledgment

The authors thank the authorities Faculty of Veterinary Medicine, Faculty of Medicine, University of Airlangga, and Dr. Soetomo General Hospital, Surabaya, East Java, Indonesia.

Conflict of interest

All authors declare that there is no conflict of interest.

References

1. Brown J, Farquhar C. Clomiphene and other antioestrogens for ovulation induction in polycystic ovarian syndrome. *Cochrane Database System Rev.* 2016;12(12):CD002249. DOI: [10.1002/14651858.CD002249.pub5](https://doi.org/10.1002/14651858.CD002249.pub5)
2. Ur-Rehman U, Ali S, Ahmad N, Khanum SA, Zubair M. Ovulation induction in pre-pubertal Sahiwal-Friesian cross bred heifers using clomiphene citrate and hCG. *Anim Reprod Sci.* 2014;149(3-4):141-144. DOI: [10.1016/j.anireprosci.2014.07.019](https://doi.org/10.1016/j.anireprosci.2014.07.019)
3. Homburg R. Clomiphene citrate: end of an era? A mini-review. *Hum Reprod.* 2005;20:2043-2051. DOI: [10.1093/humrep/dei042](https://doi.org/10.1093/humrep/dei042)
4. Nutu M, Feng Y, Egecioglu E, Weijdegard B, Victorin ES, Shao R. Stromal cell-specific apoptotic and antiestrogenic mechanism may explain uterine defects in humans after clomiphene citrate therapy. *Am J Obstet Gynecol.* 2010;203(65):1-10. DOI: [10.1016/j.ajog.2010.03.039](https://doi.org/10.1016/j.ajog.2010.03.039)
5. Speroff L, Fritz MA. *Clinical Gynecologic Endocrinology and Infertility.* 7thed. Philadelphia: Lippincott Williams & Wilkins; 2005. 13 p.

6. Maybin JA, Barcroft J, Thiruchelvam U, Hirani N, Jabbour HN, Critchley HO. The presence and regulation of connective tissue growth factor in the human endometrium. Hum Reprod. 2012;27(4):1112-1121. DOI: [10.1093/humrep/der476](https://doi.org/10.1093/humrep/der476)
7. Taylor RN, Lebovic DI, Hornung D, Mueller MD. Endocrine and paracrine regulation of endometrial angiogenesis. Ann N Y Acad Sci. 2001;94(3):109-121. DOI: [10.1111/j.1749-6632.2001.tb03795.x](https://doi.org/10.1111/j.1749-6632.2001.tb03795.x)
8. Mohammed S, Sundaram V. Comparative study of metachromatic staining methods in assessing the exfoliative cell types during the estrous cycle in Sprague-dawley laboratory rats. Int J Morphol. 2018;36(3):962-968. DOI: [10.4067/S0717-95022018000300962](https://doi.org/10.4067/S0717-95022018000300962)
9. Maae E, Nielsen M, Steffensen KD, Jakobsen EH, Jakobsen A, Sørensen FB. Estimation of immunohistochemical expression of VEGF in ductal carcinomas of the breast. J Histochem Cytochem. 2011;59(8):750-760. DOI: [10.1369/0022155411412599](https://doi.org/10.1369/0022155411412599)
10. Jakus IA, Jakus D, Aračić D, Stipičić I, Vilović K. Immunohistochemical expression of hypoxia-inducible factor-1 α in stromal cells of vaginal tissue in post-menopausal women with pelvic organ prolapse. Indian J Med Res. 2017;146(Suppl 2):S63-S67. DOI: [10.4103/ijmr.IJMR_388_16](https://doi.org/10.4103/ijmr.IJMR_388_16)
11. Kaemmerer D, Peter L, Lupp A, Schulz S, Sängler J, Baum RP, Prasad V, Hommann M. Comparing IRS and Her2 as immunohistochemical scoring schemes in gastroenteropancreatic neuroendocrine tumors. Int J Clin Exp Pathol. 2012;5(3):187-194. [\[available at\]](#)
12. Zhang B, Zhang Y. Mann-Whitney U test and Kruskal-Wallis test should be used to compare differences in medians, not means: Comment on the article by van der Helm-van Mil. Arthritis Rheum. 2009;60(5):1565. DOI: [10.1002/art.24497](https://doi.org/10.1002/art.24497)
13. Fontenot GK, Wiehle RD, Hsu K, Podolski J. The Isomers of clomiphene citrate have different dispositions once ingested: results of a mouse ADME study. J Adv Technol Clin Microbiol. 2017;1(1):1-7. [\[available at\]](#)
14. Gupta MC, Khanna J. Clomiphene citrate: the changing landscape. Int J Basic Clin Pharmacol. 2018;(8):1437-1443. DOI: [10.18203/2319-2003.ijbcp20183011](https://doi.org/10.18203/2319-2003.ijbcp20183011)
15. Amita M, Takahashi T, Tsutsumi S, Ohta T, Takata K, Henmi N, Hara S, Igarashi H, Takahashi K, Kurachi H. Molecular mechanism of the inhibition of estradiol-induced endometrial epithelial cell proliferation by clomiphene citrate. Endocrinol. 2010;151:394 - 405. DOI: [10.1210/en.2009-0721](https://doi.org/10.1210/en.2009-0721)
16. Rangwala SM, Wang X, Calvo JA, Lindsley L, Zhang Y, Deyneko G. Estrogen-related receptor gamma is a key regulator of muscle mitochondrial activity and oxidative capacity. J Biol Chem. 2010;285:22619-22629. DOI: [10.1074/jbc.M110.125401](https://doi.org/10.1074/jbc.M110.125401)
17. Elkind-Hirsch KE, Phillips K, Bello SM, McNicho M, de Ziegler D. Sequential hormonal supplementation with vaginal estradiol and progesterone gel corrects the effect of clomiphene on the endometrium in oligo-ovulatory women. Hum Reprod. 2002;17(2):295-298. DOI: [10.1093/humrep/17.2.295](https://doi.org/10.1093/humrep/17.2.295)
18. Taheripannah R, Kabir-Salmani M, Favayedi M, Zamaniyan M, Malih N, Taheripannah A. Effects of clomiphene citrate plus estradiol or progesterone on endometrial ultrastructure: An RCT. Int J Reprod BioMed. 2020;18:201-208. DOI: [10.18502/ijrm.v18i3.6718](https://doi.org/10.18502/ijrm.v18i3.6718)
19. Yagel S, Ben-Chetrit A, Anteby E, Zacut D, Hochner-Celnikier D, Ron M. The effect of Ethinyl estradiol on endometrial thickness and uterine volume during ovulation induction by clomiphene citrate. Fertil Steril. 1992;57(1):33-36. DOI: [10.1016/s0015-0282\(16\)54772-4](https://doi.org/10.1016/s0015-0282(16)54772-4)
20. Mueller MD, Vigne JL, Minchenko A, Lebovic DI, Leitman DC, Taylor EN. Regulation of vascular endothelial growth factor (VEGF) gene transcription by estrogen receptors. PNAS. 2000;97(20):10972-10977. DOI: [10.1073/pnas.200377097](https://doi.org/10.1073/pnas.200377097)
21. De Francesco EM, Pellegrino M, Santolla MF, Lappano R, Ricchio E, Abonante S, Maggiolini M. GPER mediates activation of HIF1 α /VEGF signaling by estrogens. Cancer Res. 2014;74(15):4053-4064. DOI: [10.1158/0008-5472.CAN-13-3590](https://doi.org/10.1158/0008-5472.CAN-13-3590)
22. Losordo D, Isner JM. Estrogen and angiogenesis. Arterioscler Thromb Vasc Biol. 2001;21(1):6-12. DOI: [10.1161/01.ATV.21.1.6](https://doi.org/10.1161/01.ATV.21.1.6)
23. Sudhagar S, Sathya S, Lakshmi BS. Rapid non-genomic signaling by 17 β -oestradiol through c-Src involves mTOR-dependent expression of

HIF-1 α in breast cancer cells. Br J Cancer. 2011;105:953-60. DOI: [10.1038/bjc.2011.349](https://doi.org/10.1038/bjc.2011.349)

مستوى تعبير بطانة الرحم للأستروجين ألفا و VEGF-A في إناث الجرذان المعاملة بجرعة منخفضة من الأستروجين في المراحل المبكرة من العلاج بسيترات الكلوميفين

رحمت لانداهور^١، بودي سانتوسو^١، ويدجياتي ويدجياتي^٢ و إبيي محمد لقمان^٢

^١ قسم التوليد والأمراض التناسلية، كلية الطب، ^٢ قسم العلوم البيطرية، كلية الطب البيطري، جامعة إيرانغا، سورابايا، إندونيسيا

الخلاصة

أجريت الدراسة لتحديد تأثير إعطاء جرعة منخفضة من الأستروجين في المراحل المبكرة من العلاج بسيترات الكلوميفين على مستوى تعبير مستقبلات الأستروجين ألفا (ER α) و VEGF-A في بطانة الرحم. الدراسة الحالية عبارة عن دراسة تجريبية أجريت على ٢٩ من إناث الجرذان البالغة بعمر ثلاثة أشهر ووزن ١٥٠-٢٠٠ جرام. قسمت إناث الجرذان عشوائياً إلى ثلاث مجاميع (C: دواء وهمي؛ T1: عولجت بجرعة واحدة من ستترات الكلوميفين (١٠٠ ملغ/كغم من وزن الجسم، فمويًا)؛ T2: أعطيت علاج مركب من سيتترات الكلوميفين (١٠٠ ملغ/كغم من وزن الجسم، فمويًا، جرعة واحدة) وأسترايديول فاليريت (١٥ بيكوغرام/كغم من وزن الجسم، فمويًا، جرعة واحدة). فحصت عينات الرحم للتعبير عن مستقبلات هرمون الأستروجين ألفا و VEGF-A باستخدام الكيمياء النسيجية المناعية. أظهرت النتائج وجود فرق معنوي في نسبة الأستروجين ألفا في المجموعة C مقارنة بمجموعتي T1 و T2. في حين، لم يكن هناك فرق معنوي بين المجموعتين T1 و T2. كانت النسبة المئوية لتعبير VEGF-A في المجموعة C مختلفة معنوياً مقارنة مع T1 و T2. في حين، لم يكن هناك فرق معنوي بين المجموعتين T1 و T2. بالخلاصة، لم ينتج عن إعطاء جرعة منخفضة من الأسترايديول فاليريت في المراحل المبكرة من العلاج بسيترات الكلوميفين أي تأثير معنوي على تعبير مستقبلات الأستروجين ألفا و VEGF-A في بطانة الرحم.