

The role of adding hyaluronic acid in the grafting process for the repair of an experimentally induced tibial defect in dogs' model

F.M. Mohammed¹, L.M. Alkattan¹, A.M. Shareef², and H.Kh. Ismail³

¹Department of surgery and theriogenology, College of Veterinary Medicine, University of Mosul, ²Department of Radiology, College of Medicine, Nineveh University, ³Department of Pathology and Poultry Diseases, College of Veterinary Medicine, University of Mosul, Mosul, Iraq

Article information

Article history:

Received July 22, 2021

Accepted October 29, 2021

Available online May 1, 2022

Keywords:

Hyaluronic acid

Ribs xenograft

Tibia defect

Dog

Correspondence:

L.M. Alkattan

laythalkattan@uomosul.edu.iq

Abstract

The study is designed to determine the role of adding hyaluronic acid as a supportive filling material to improve experimentally defective tibial bone grafting in the dog model. Eighteen local breed dogs of both sexes weighted 18 ± 0.4 kg and aged 12 ± 0.6 months were randomly allocated in two equal groups. Twelve dogs underwent experimental tibial bone defect 2.5×0.7 cm in the first group and were replaced with deproteinized lamb ribs. The second group was treated like that first and supported 1% hyaluronic acid to their grafts. The bone in both groups was firmly fixed by cerclage wire. All dogs were followed up clinically, radiologically, and macroscopically at 14, 30, and 60 days after the intervention. In all study dogs, the signs of the systemic infection of seromas, hematoma, and severe lameness were not developed along the study period. Grossly, dogs in the second group at 60 days showed an increase in the size of the filler of bone at the edges and the mid of the defect, improvement and acceleration in the bone healing, and formation of bone bridges compared to the first group. Radiological findings exhibited complete healing of the fixated bone segment with the surrounding area; however, some cortical irregularities denoted chronic periosteal reaction and callus formation in the treatment with hyaluronic acid. In conclusion, the study indicated that hyaluronic acid with xenograft materials exhibited remarkably beneficial effects on improving the augmentation of the tibial bone defect.

DOI: [10.33899/ijvs.2021.130889.1891](https://doi.org/10.33899/ijvs.2021.130889.1891), ©Authors, 2022, College of Veterinary Medicine, University of Mosul.

This is an open access article under the CC BY 4.0 license (<http://creativecommons.org/licenses/by/4.0/>).

Introduction

Critical bone defect repairing represents a significant challenge due to the difficulty of restoring the mechanical and esthetic features of the bone (1). The tibial bone defect and fracture represent 13.81% of bone defects in dog (2). Bone replacement might have been practiced for centuries with various materials of natural origin. These materials can be derived either from biological products such as demineralized bone matrix, platelet-rich plasma, hydroxyapatite, adjunction of growth factors (like bone morphogenetic protein), or synthetic products such as

calcium sulfate, tri-calcium phosphate ceramics (3-5). Nowadays, many different materials can be used to fill bone defects allogenic bone, xenogeneic bone, or bone substitutes which are defined as “synthetic, inorganic or biologically organic combinations which can be inserted for the treatment of a bone defect instead of autogenous or allogeneous bone (6). Xenograft bone material has been used experimentally by some researchers as a bone substitute (7). Bone tissue, which is self-renewal and modeling tissue life-long, is the only tissue that can heal without scarring. (8). However, bone tissue fails to self-heal the defect in defects over specific sizes. Such defects are called critical-size defects,

and various biomaterials or bone grafts are then used in their reconstruction (9). Bone grafts can be harvested from the wing of the ileum, and Surgical complications can be non-union, proximal humerus, proximal tibia, distal radius, rejection, fracture (as fixation loosens), premature Sternum, and ribs (10). Different bioactive materials were used to repair bone (11) and another tissues as tendon (12,13). One of the most bioactive materials used in bone grafting processes is Hyaluronic acid (HA), a natural compound found in many tissues such as linear polysaccharides of the extracellular matrix of connective tissue, synovial fluid, and other tissues (14) with no antigenic specificity for species or tissues; thus, there is a low potential allergic or immunogenic reaction. On the other side, HA has an essential anti-inflammatory role via inhibition of tissue destruction and facilitation of tissue healing (15). The study aimed to determine the role of adding hyaluronic acid as supporting filling materials to the grafting process of experimentally defective tibial bone in the dog model.

Materials and methods

This study included eight healthy local breed dogs from both sexes weighted 18 ± 0.4 kg and aged 12 ± 0.6 Months. The animals were randomly allocated into two equal groups that underwent the same conditions along the work period. The anesthesia protocol was administrated intramuscularly to the animals and included a mixture of 10% Ketamine 5mg Alfasan, Holland \ 2% Xylazine, Alfasan, Holland 5mg kg BWt respectively (16).

In the first group, an experimental bone defect was created by electrical saw at the medial aspect of the proximal portion of the tibial bone in the dog at 2.5 by 0.7 cm. Deproteinized lamb ribs were used as xenografts to replace the defective bone, prepared according to (17). The lamb ribs were aseptically harvested directly from the slaughterhouses and put in the sterile normal saline, then soft tissue, periosteum, and fat were stripped off by scalpel and sterile gauze. These ribs were cut into graft segments of 2.4 by 0.6 cm. The grafts were defatted with chloroform and ethanol 96% (1:1) for 12 hours at 25 C, deproteinization procedures of the xenograft by putting it in the pepsin 1% then put in a warm bath at temperature 37°C for 48 hours and washing with distal water. We then prepared grafts still under deep freeze -80°C. The prepared xenograft was thawed to repair the experimental bone defect and immobilized by cerclage wire to fix the graft. In the second group, the preparations of graft and operation were similarly performed as in the first group except that the graft was supported with hyaluronic acid 1%, which was considered filling materials (Figure 1 and 2). All treated animals underwent the same surgical procedures and conditions during the period of the experiment. Clinical, radiological, and gross examinations were investigated during the study. The gross examination

included swelling, firm application, and fixation of xenograft, the healing process. Clinical examination included degree of lameness and in operated leg at 0 time and 7,14 and 60 days postoperative.

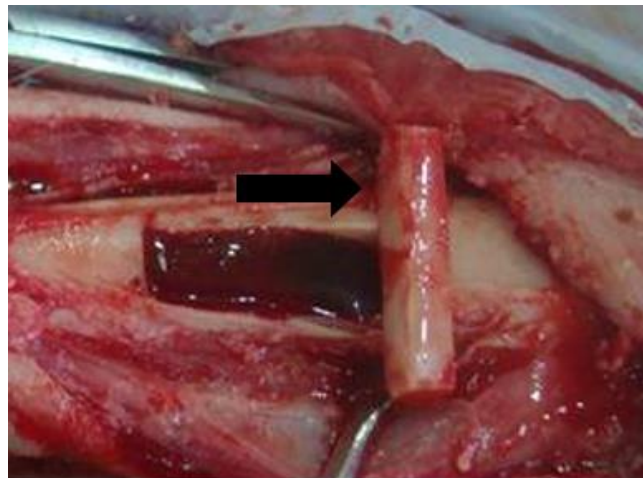


Figure 1: Experimental bone defect, the arrow shows the deproteinized lamb rib xenograft.

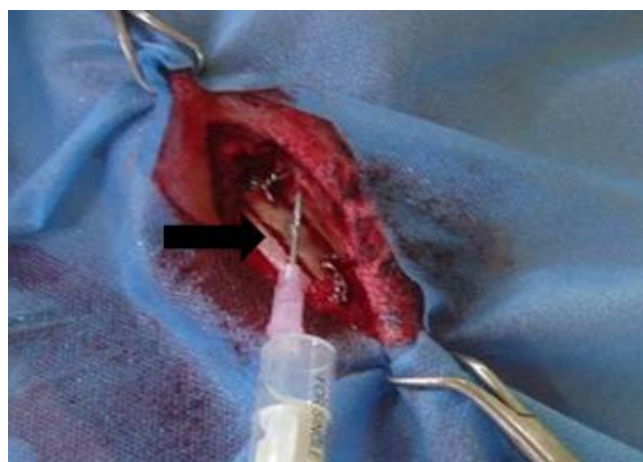

Figure 2: Fixation of xenograft supported with hyaluronic acid 1%.

Results

The results showed that none of the treated animals underwent outward signs of seromas, or severe hematoma lameness was not developed along the study period in all operative groups; however, there were signs of local heat, and pain that continued for few days then subsided gradually. The gross examination at 14,30- and 60-days postoperative reveals firm fixation of bone xenograft in both groups with no signs of graft rejection. In the first group, treatment with

xenograft only at the period of 14, 30 days postoperative showed that the edges of all tibial defect bone were covered with a dense and thick layer of fibrous connective tissue on the edges of the defects of the tibial bone (Figures 3 and 4). In comparison, after 60 days of operation, the gross appearance on the edges of the defect showed bone formation on the edges in the mid-portion of the defect (Figure 5). In the second group, animals treated with xenograft with hyaluronic acid showed improvement in the healing of the defect bone 14 days interval of the experiment group. Gross examination showed mature fibrous connective tissue filling on the edges and mid-portion of the defects (Figure 6). At 30 days post-operation, the defect was filled with new bone. The radiological examination revealed that the bone healing process has occurred at new bone formation and the bone healing process at the fibrous callus stage (Figure 7). At 60 days, there was an increase in the bone filler at the edges, and in the mid of the defect, a formation of bone bridges was found. The best new bone formation was investigated by the radiographs (Figure 8).

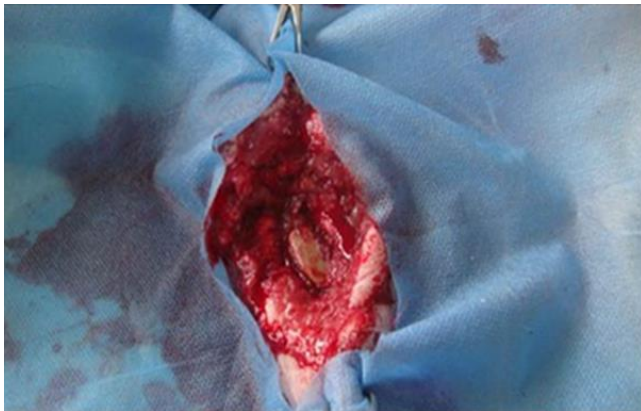

Figure 3: Gross examination of the first group at 14 days postoperative.

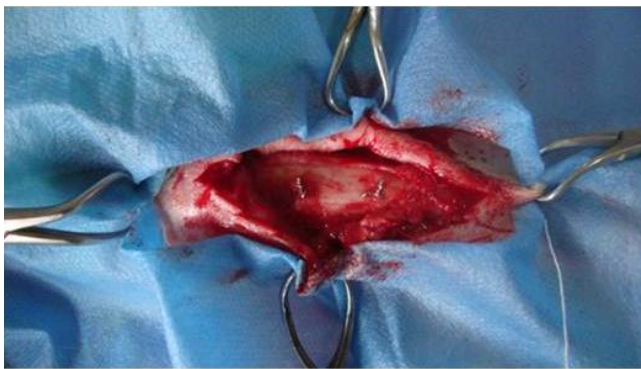


Figure 4: Gross examination of the first group at 30 days postoperative.

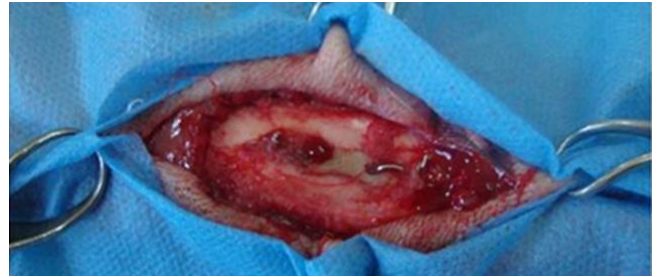

Figure 5: Gross examination of the first group at 60 days postoperative.

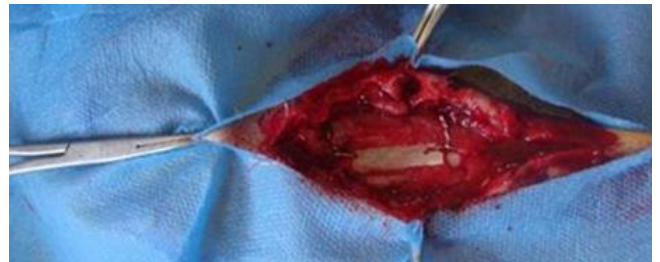

Figure 6: Gross examination of the second at 14 days postoperative.

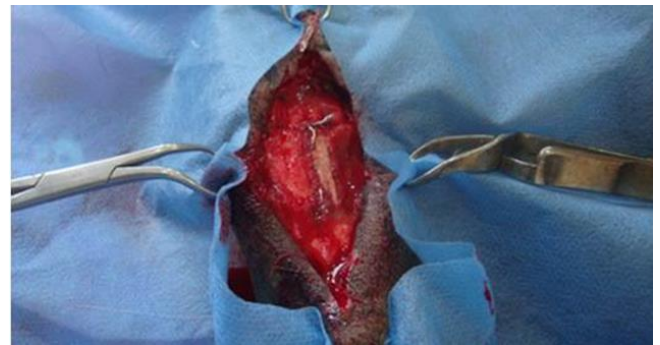

Figure 7: Gross examination of the second group at 30 days postoperative.

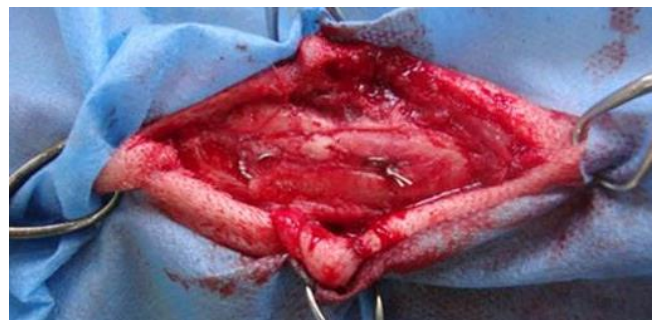


Figure 8: Gross examination of the second group at 60 days postoperative.

Our radiographic findings in the first group at 14 days Lateral view reveals lucent line surrounding the fixated bone graft, associated with mild soft tissue swelling surrounding the area. However, no definite periosteal reaction nor significant callus have been formed (Figure 9). At thirty days postoperative thin lucent line surrounding the fixated bone segment was formed (Figure 10). At 60 days in the control group, the investigations revealed complete healing of the fixated bone segment with the surrounding area; however, some cortical irregularities denoting chronic periosteal reaction and callus formation (Figure 11). In the treatment group at 14 days, the results revealed a lucent line surrounding the fixated bone segment, associated with minimal soft tissue swelling surrounding the area; however, early periosteal reaction but no significant callus formation was revealed (Figure 12). At 30 days after treatment, there is cortical irregularity and thickening with loss of the lucent line defect surrounding the fixated bone segment denoting late-stage periosteal reaction with good callus formation and healing process (Figure 13), whereas the treated group with hyaluronic acid showed complete healing of the fixated bone segment with the surrounding area; however, some cortical irregularities denoting chronic periosteal reaction and callus formation. In addition, there was a focal cortical Lucent area surrounded by soft tissue swelling (Figure 14).

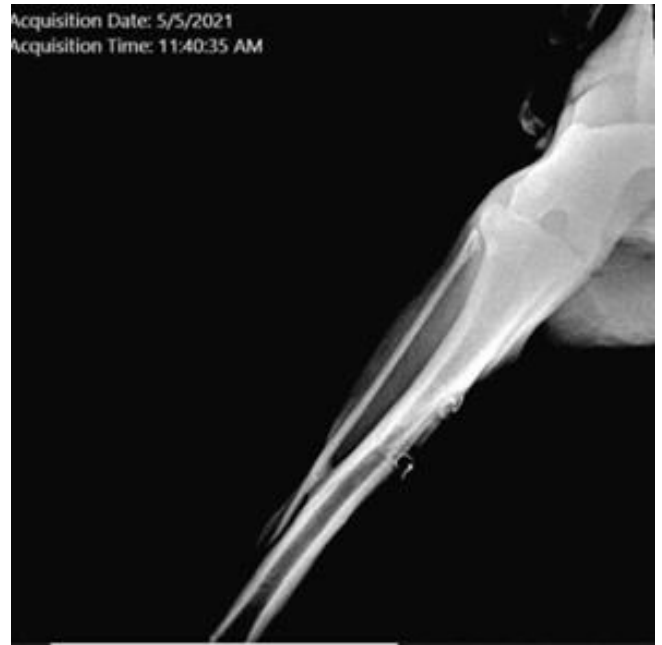


Figure 10. Radiological picture treatment in the first group at 30 days postoperative.

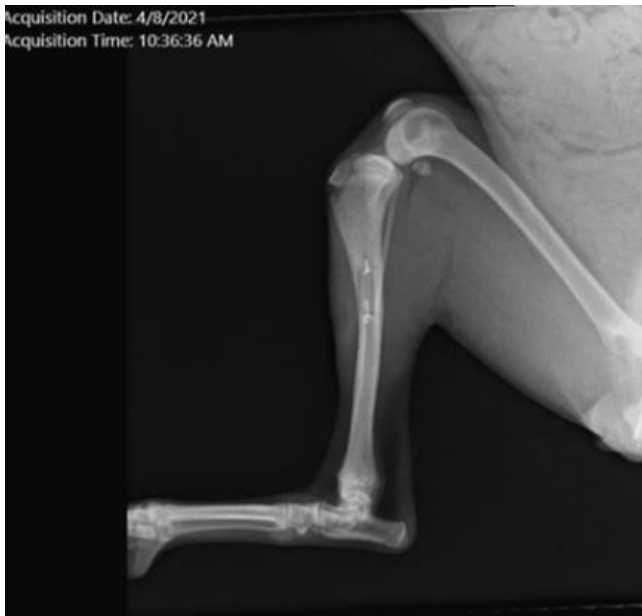

Figure 9: Radiological picture in the first group at 14 days postoperative.

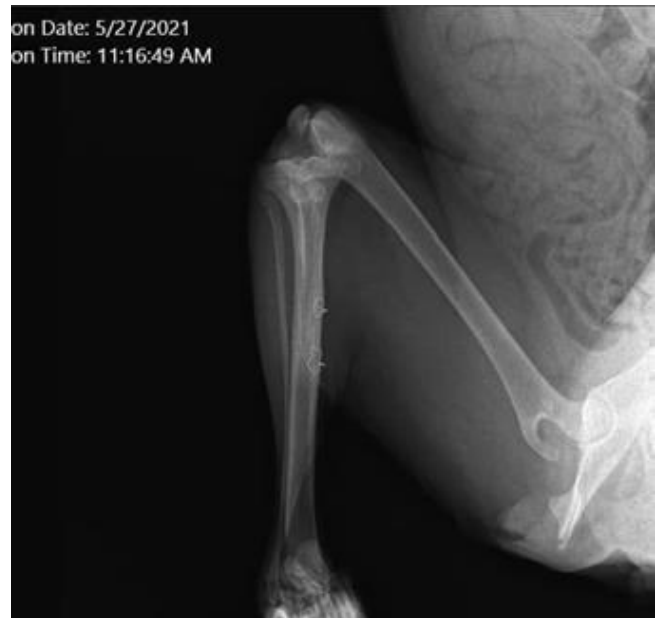

Figure 11: Radiological picture in the first group at 60 days postoperative.

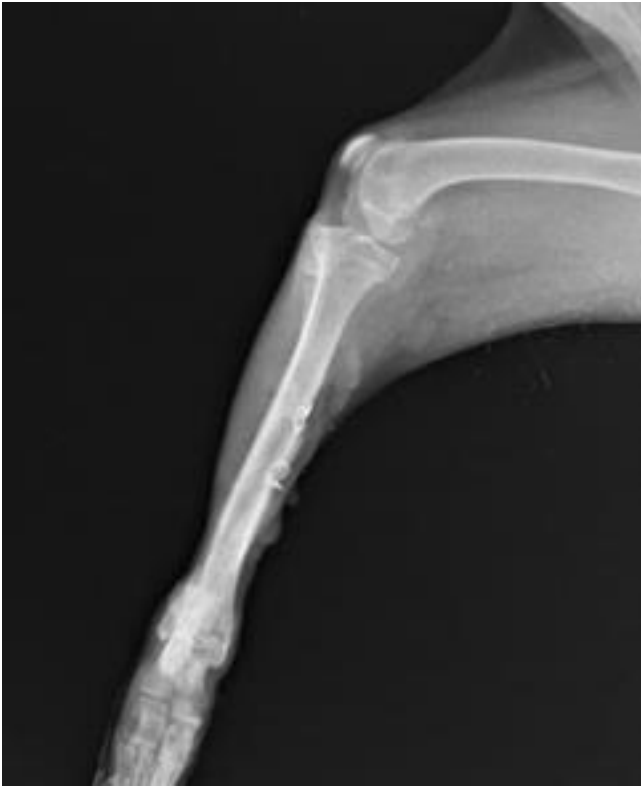

Figure 12: Radiological picture in the treatment group with hyaluronic acid at 14 days postoperative.

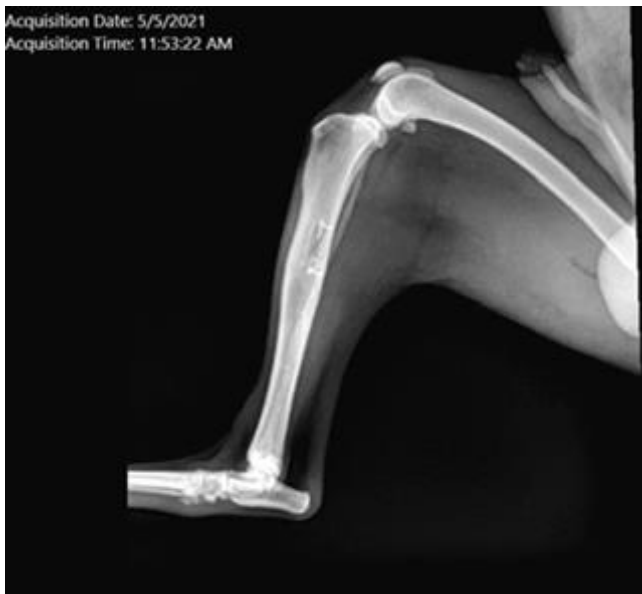

Figure 13: Radiological picture in the treatment group with hyaluronic acid at 30 days postoperative.

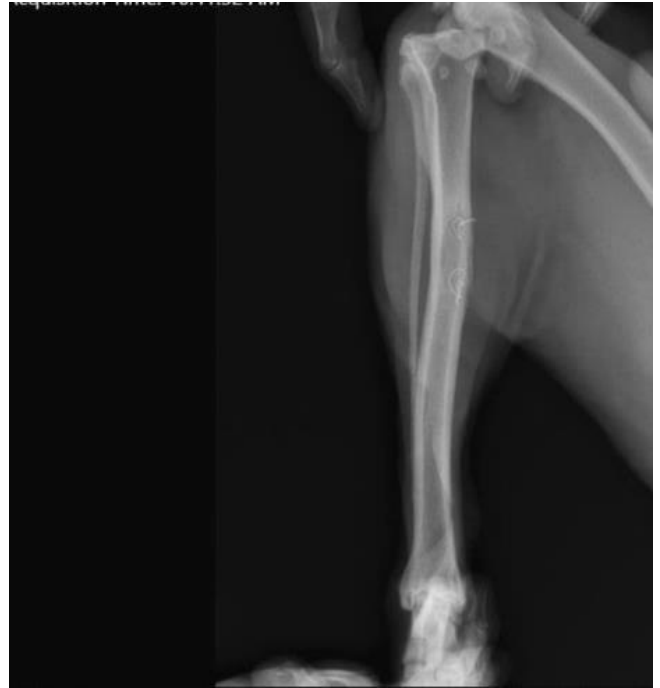

Figure 14: Radiological picture in the treatment group with acid hyaluronic (lateral view) at 60 days postoperative.

Discussion

The bone regenerative process and cascade steps of repairing tibial bone defects were investigated in this study. Hyaluronic acid, known as hyaluronan and hyaluronate, is effective in the early stages of bone morphogenesis and osteogenesis, binds to fibrin, fibrinogen, fibronectin, and collagen is essential for wound healing, in addition. HA plays a vital role in different biological processes, modified with various chemicals to help in producing mechanical and chemical durable HA-based biomaterials. Various HA-based bioactive materials were used in many fields, such as orthopedics surgery, ophthalmology, dentistry, and dermatology (18). The results indicated that the healing process was accelerated by using hyaluronic acid with xenograft. Radiologically, better healing was observed in this group in comparison to the group using xenograft only.

Moreover, hyaluronic acid has osteoconductive potential by accelerating bone regeneration via chemotaxis proliferation and differentiation of mesenchymal cells hyaluronic acid, sanatura (non-sulfated light molecular weight glycosaminoglycan that forms a critical component of extracellular matrix and contributes to cell migration and proliferation. Radiological investigation of the operative group in the current study showed interdependence between the experimental defect edges and bone segment, which allowed bone tissue regeneration to occur, especially from

the periphery to the graft. This may be related to the osteoconductive properties of graft (19-21). Our study indicated that the deproteinized lamb bone graft fulfilled almost all achievement properties for bone repairing. This finding agreed with Ibrahim *et al.* (22) who used innovative scaffolds mixture from dextran, nanoparticles, gelatin, hydroxyapatite for bone reconstruction and restoration. However, in our study, bone graft played an essential role as a scaffold in bone tissue restoring near the standard furniture of defective bone and served as a bridge to improve the healing and achieve a perfect clinical outcome (23). HA served as supportive filling bioactive material improving osteogenesis and mineralization of defective bone rather than serving as scaffolds (24). The healing process was excellent in the treatment group with HA because the osteoprogenitor cells can migrate and firmly adhere to the graft. Finally, the ends of the defect were filled with new bony tissue, which agreed with what was found in Goel *et al.* (19).

Conclusion

Our study indicated that hyaluronic acid with xenograft materials exhibited beneficial effects on improvement of the tibial bone defect augmentation.

Acknowledgments

We warmly give our gratitude to the College of Veterinary Medicine, University Mosul, for their continuous support and encouragement during the work and preparation of the manuscript.

Conflict of interest

The manuscript has no conflict of interest.

Reference

- Huang RL, Kobayashi E, Liu K, Li Q. Bone graft prefabrication following the in vivo bioreactor principle. *Bio Med.* 2016;12:43-54. DOI: [10.1016/j.ebiom.2016.09.016](https://doi.org/10.1016/j.ebiom.2016.09.016)
- Sozan AM, Othman J A, Bahjat AT, Hardi F M, Rizgar RS, Brwa MA, Dekan AR, Harem HH, Ali G and Mustafa AD. A retrospective study of fracture cases managed in the veterinary teaching hospital;181 cases (2014-2018). *Iraqi J Vet Sci.* 2021;35(1):23-31. DOI: [10.33899/ijvs.2020.126228.1266](https://doi.org/10.33899/ijvs.2020.126228.1266)
- Sozan AM, Othman JA, Bahjat TA, Hardi FM, Rizgar RS, Brwa MA, Dekan AR, Harem HH, Ali G, Mustafa A, Gashaw M A, Grado G, Keller L, Gillet Y, Wagner Q, Musset A, Jessel N, Bornert F, and Offner D. Bone substitutes a review of their characteristics, clinical use, and perspectives for large bone defects management. *J Tissue Eng.* 2018;9:1. DOI: [10.1177/2041731418776819](https://doi.org/10.1177/2041731418776819)
- Peltola M. Bioactive glass in frontal sinus and calvarial bone defect obliteration. *Experimental and Clinical Studies [PhD dissertation]. Turkey: Annales Universitatis Turkuensis;* 2001. 45-47 p.
- Mahmood SK, Abdul R, Yaseen MT, Yusof LM, Mahmood ZK, Gimba FI, Zakaria ZB. 3-D nanocomposite scaffolds:Tissue engineering for bone reconstruction. *Iraqi JVet Sci.* 2022;36(2):433-444. DOI: [10.33899/ijvs.2021.130481.1831](https://doi.org/10.33899/ijvs.2021.130481.1831)
- Schlickewie W, Schlickewie C. The use of bone substitutes in the treatment of bone defects: The clinical view and history. *Macromol Symp.* 2007;253:10-23. DOI: [10.1002/masy.200750702](https://doi.org/10.1002/masy.200750702)
- Young C, Sandstedt P, Skoglund A. A comparative study of anorganic xenogeneic bone and autogenous bone implants for bone regeneration in rabbits. *Int J Oral Maxillo Fac Implants.* 1999;14(1):72-6. [\[available at\]](#)
- Shapino F. Bone development and its relation to fracture repair. The role of mesenchymal osteoblasts and surface osteoblasts. *Eur. Cell Mater.* 2008;15:53-76. DOI: [10.22203/ECM.v015a05](https://doi.org/10.22203/ECM.v015a05)
- Amini AR, Laurencin CT, Nukavarapu SP. Bone tissue engineering: Recent advantages challenges. *Crit Rev Biomed Eng.* 2012;40:363-408. DOI: [10.1615/critrevbiomedeng.v40.i5.10](https://doi.org/10.1615/critrevbiomedeng.v40.i5.10)
- Johnson AL. Principles of bone grafting. *Semin Vet Med Surg Small Anim.* 1991;6:90-99. [\[available at\]](#)
- Stern R, Asari AA, Sugahara KN. Hyaluronan fragments: An information-rich system. *Eur J Cell Biol.* 2006;85(8):699-715. DOI: [10.1016/j.ejcb.2006](https://doi.org/10.1016/j.ejcb.2006)
- Allawi AH, Alkattan LM, Al Iraqi OM. Clinical and ultrasonographic study of using autogenous venous graft and platelet-rich plasma for repairing Achilles tendon rupture in dogs. *Iraqi J Vet Sci.* 2019;33(2):453-460. DOI: [10.33899/ijvs.2019.163199](https://doi.org/10.33899/ijvs.2019.163199)
- Allawi AH, Alkattan LM, Al Iraqi OM. The Effect of Autogenous Peritoneal Graft Augmented with Platelets- Plasma Rich Protein on the Healing of Induced Achilles Tendon Rupture in Dogs. *Iran J Vet Med.* 2020;14:2. DOI: [10.ijvm.2020.291379.1005037](https://doi.org/10.ijvm.2020.291379.1005037)
- Benedetti L, Cortivo R, Berti A, Pea F, Mazzo M, Moras M, Abatangelo G. Biocompatibility and biodegradation of different hyaluronan derivatives (HYAFF) implanted in rats. *Biomaterials.* 1993;14:1154-1160. DOI: [10.1016/0142-9612\(93\)90160-4](https://doi.org/10.1016/0142-9612(93)90160-4)
- Peattle RA, Nayate AP, Firpo MA, Shelby J, Fisher RJ, Prestwich GD. Stimulation of in vivo angiogenesis by cytokine-loaded hyaluronic acid hydrogel implants. *Biomaterials.* 2004;25(14):2789-98. DOI: [10.1016/j.biomaterials.2003.09.054](https://doi.org/10.1016/j.biomaterials.2003.09.054)
- Green S, Thurmon JC. Xylazine is a review of its pharmacology and uses in vet medicine. *J Vet Pharmacol Therap.* 1988;11:295-313. DOI: [10.1111/j.1365-2885.1988.tb00189.x](https://doi.org/10.1111/j.1365-2885.1988.tb00189.x)
- Pengfei L, Rongxin S, Wang L, Jialin Z, Lifei W, Tianjian Z, Yihe H A. New Method for Xenogeneic Bone Graft Deproteinization: Comparative Study of Radius Defects in a Rabbit Model, *Plos One.* 2015;10(12):45-46. DOI: [10.1371/journal.pone.0146005](https://doi.org/10.1371/journal.pone.0146005)
- Stern M, Schmidt B, Dodson T, Stern B, Kaban LB. Fetal cleft lip repair in rabbits: Histology and role of hyaluronic acid. *J Oral Maxillofac Surg.* 1992;50(3):263-8. DOI: [10.1016/0278-2391\(92\)90323-r](https://doi.org/10.1016/0278-2391(92)90323-r)
- Goel SC, Singh D, Rastogi A, Kumaraswamy V, Gupta A, Sharma N. Role of tricalcium phosphate implant in bridging the significant osteoperiosteal gaps in rabbits. *Indian J Exp. Biol.* 2013;51(5):375-380. [\[available at\]](#)
- Tool BP. Hyaluronic in morphogenesis. *Semin Cell Dev Biol.* 2001;12:79-27. DOI: [10.1006/scdb.2000.0244](https://doi.org/10.1006/scdb.2000.0244)
- Wafaa KA, Yusra HM. Repair of surgical bone defects grafted with hydroxylapatite + β -TCP combined with hyaluronic acid and collagen membrane in rabbits: A histological study. *J Taibah Univ Med Sci.* 2019;3;14(1):14-24. DOI: [10.1016/j.jtumed.2018.12.001](https://doi.org/10.1016/j.jtumed.2018.12.001)
- Ibrahim SM, Mahmood SK, Razak IS, Yusof LM, Mahmood ZK, Gimba FI, Zakaria MZ. Characterization and in vitro evaluation of a novel coated nanocomposite porous 3D scaffold for bone repair. *Iraqi J Vet Sci.* 2019;33(1):157-173. DOI: [10.33899/IJVS.2019.125548.1068](https://doi.org/10.33899/IJVS.2019.125548.1068)
- Wang C, Huang W, Zhou Y, He L, He Z, Chen Z, He X, Tian S, Liao J, Lu B, Wei Y, Wang M. 3D printing of bone tissue engineering scaffolds. *Bioactive Materials.* 2020;5(1):82-91. DOI: [10.1016/j.bioactmat.2020.01.004](https://doi.org/10.1016/j.bioactmat.2020.01.004)
- Zhai P, Peng X, Li B, Liu Y, Sun H, Li X. The application of hyaluronic acid in bone regeneration. *Intern J Biol Macromolecules.* 2020;151:1224-1239. DOI: [10.1016/j.ijbiomac.2019.10.169](https://doi.org/10.1016/j.ijbiomac.2019.10.169)

عشوائي في مجموعتين متساويتين، وخضعت حيوانات المجموعة الأولى الى عيب تجريبي في عظم القصبة $0,7 \times 2,5$ سم وتم إصلاح العيب برقع مغايره من ضلع الضأن، أما في المجموعة الثانية تم معاملتها بنفس الطريقة المستخدمة للمجموعة الأولى مع استخدام حمض الهيالورونيك بنسبة 1٪ كمادة داعمة للرقع المغايرة، تم تثبيت الرقع في كلتا المجموعتين بإحكام بواسطة سلك تطويق. تم إجراء الفحوصات السريرية والشعاعية والميكروسكوبية ولقترات 14، 30 و 60 يوماً. لجميع الحيوانات التي خضعت للعملية الجراحية، لم تظهر أية أصابه جهازية بالخمج وعلامات التورم المصلي والورم الدموي والعرج الشديد طوال فترة الدراسة. عيانيا في المجموعة الثانية بعد 60 يوما من العملية هناك زيادة في تكون النسيج العظمي وملئ للفراغات عند حواف ومنتصف العيب المحدث وهناك تحسن وتسريع في التئام العظام، وأيضا هنالك تكوين لجسور العظام مقارنة بالمجموعة الأولى. أظهرت نتائج الفحص الشعاعي شفاءً كاملاً للجزء العظمي المثبت مع المنطقة المحيطة مع وجود قشور منتظمة والتي تدل على تفاعل سمحافي مزمّن وتكوين الدشبذ في المجموعة المعالجة بحامض الهيالورونيك. وخلاصة لما ذكر تشير دراستنا إلى أن استخدام حامض الهيالورونيك مع الرقع المغايرة أظهر نتائج مفيدة ملحوظة في تحسين إعادة ترتيب عيب عظام قصبه الساق.

دور إضافة حمض الهيالورونيك لدعم عمليات الترقيع خلال إصلاح العيب المحدث تجريبيا لعظم قصبه الساق في الكلاب

فؤاد مؤيد محمد¹، ليث محمود القطان¹، احمد مذخر شريف² و
هناء إسماعيل خليل³

¹ فرع الجراحة وعلم تناسل الحيوان، كلية الطب البيطري، جامعة الموصل، فرع الأشعة، كلية الطب، جامعة نينوى، فرع الأمراض وأمراض الدواجن، كلية الطب البيطري، جامعة الموصل، الموصل، العراق

الخلاصة

صممت الدراسة لتحديد دور إضافة حمض الهيالورونيك كمادة حشو داعمة لتحسين عملية ترقيع العيب المحدث تجريبيا لعظم القصبه في الكلب تم استخدام ثمانية عشر محلي من الكلاب السائبة ومن كلا الجنسين وزنها $0,4 \pm 1,8$ كجم وعمرها $0,6 \pm 1,2$ شهرا تم تقسيم الكلاب بشكل