

## Orf disease in local goat; clinical and phylogenetic study in Al-Qadisiyah governorate, Iraq

Kh.A. Mansour<sup>1</sup>, M.H. Hussain<sup>1</sup>, A.J. Abid<sup>1</sup> and Q.H. Kshash<sup>1</sup>

Department of Veterinary Internal and Preventive Medicine, College of Veterinary Medicine, University of Al-Qadisiyah, Al-Qadisiyah, Iraq

### Article information

#### Article history:

Received February 20, 2021

Accepted May 20, 2021

Available online November 20, 2021

#### Keywords:

Goat

Orf

GIF Gene

Skin

Scabs

#### Correspondence:

M.H. Hussain

[muthanna.hussain@qu.edu.iq](mailto:muthanna.hussain@qu.edu.iq)

### Abstract

This study aimed to diagnose orf virus ORFV from infected goats in Al-Qadisiyah Governorate of Iraq, using polymerase chain reaction and construction of phylogenetic tree. Clinical examination was made on 400 goats in different herds and crusty scabs were collected from forty infected goats. All scabs were subjected to (PCR), sequencing, and phylogenetic analysis involving the presence of GIF gene GM-CSF inhibitor factor, a characteristic gene of the ORFV. The typical proliferative skin lesion with overall orf prevalence results by PCR was 10% with low mortality rates and high significance variation with age and gender. Two positive PCR amplicons were sent for partial-gene-based sequencing and Phylogenetic analysis. Multiple alignments of sequences presented close identities with two Iraqi global isolates of the virus. This study didn't only report novel sequences from the local orf virus isolates, but it also provides important data about transmission of local sheep orf virus into local goat during closely rearing and grazing and orf outbreak in small ruminant in Iraq might be suspected.

DOI: [10.33899/ijvs.2021.129489.1651](https://doi.org/10.33899/ijvs.2021.129489.1651), ©Authors, 2022, College of Veterinary Medicine, University of Mosul.

This is an open access article under the CC BY 4.0 license (<http://creativecommons.org/licenses/by/4.0/>).

### Introduction

ORF' is recognized as sore and scabby mouth disease, contagious ecthyma, and contagious pustular dermatitis, considered one of the most important viral skin diseases in goat farms. It mainly affects sheep, goat and some other housetrained and wild ruminants, causing economic loss in the livestock construction. (1). Disease is spread worldwide and widespread in many countries wherever sheep and goats are owned, and the disease also has zoonotic latent affecting the farmers, veterinarians and butchers who are in direct interaction with infected animals especially during shearing, docking, drenching and slaughtering or indirect connection with infected animals (2). The spread within a group is carried out over direct contact between animals during a confrontation or suckling. Morbidity is actually higher in young animals and mortality is usually low, but it may be very great when bacterial or fungal secondary infections occur (3). Orf causes highly economic losses

including weight loss, premature culling, treatment and control costs. Many studies indicate the world wide and very high incidence of orf infection in goat herds as in China 60% (4), 14.4% in Malaysia (5) in Korea (6), in India (7). In Africa, orf contagion has been stated in sheep and goats in certain countries such as Cameroon, Nigeria, Tanzania and Egypt (8), Gabon (9), in Brazil (10). Clinically, orf develops from erythema to macule, papule, vesicle creation and at that time pustules to dense crusts called scabs. The scabs are often friable and minor trauma makes the lesions bleed simply. These lesions are ordinarily started on muzzle, lips, oral mucosa, ears and round the nostrils. The lesions can also be gotten on feet, eyelids and teats (11). Suspected orf disease can be identified based on clinical signs, tracked by laboratory tests such as serum neutralization test (SNT), electron microscopy, histopathology of the infected tissues and polymerase chain reaction (PCR) (12). Polymerase chain reaction is a consistent method for the diagnosis and can distinguish

ORFV from other pox viruses such as sheep pox and goat pox (13). Numerous molecular investigative approaches including PCR and quantitative PCR (qPCR) have been established to distinguish orf virus (14).

The present study aimed to detect ORFV in Iraqi goat based on the GIF gene which is responsible for inhibiting the ovine cytokines Granulocyte-Macrophage Colony-Stimulating Factor (GM-CSF) and interleukin-2 (IL-2) as a unique feature and the significant of age and gender on the prevalence rate of Orf (15).

## Materials and methods

### Ethics statement

Scabs were collected from goat during this study for diagnosis. No animal experimentation was accompanied and sample gathering and procedures were permitted by the cooperative animal ethical committee of College of Veterinary Medicine, Al-Qadisiyah University. All labors were finished to lessen animal pain during the development of sample gathering in orf suspected sickness. Consent was gotten from the animal possessors for the assortment of tissue samples by veterinarian authorities.

### Sampling

The study was planned to be done from December, 2018 to January, 2019 in the rural part of Al-Dagharah district positioned in the north east of Al-Qadisiyah province approximately on latitude 31.58°N, longitude 44.500°E. in the middle of Iraq (Figure 1).

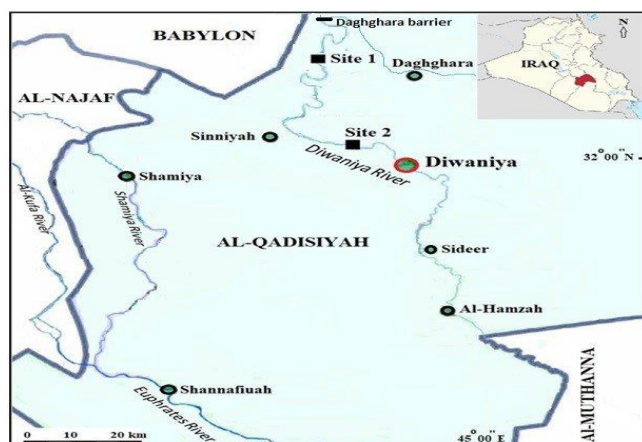


Figure 1: Study location, Al-Dagharah district in Al-Qadisiyah province, Iraq (google maps).

Forty goats had suspected with clinical orf include crusty external skin lesions on the muzzle, nostrils and lips, goats were dull and depressed, they were 28 kids (18 females and 10 males) and 12 adults (8 females and 4 males), they reported after examination of three separated private goat flocks. Clinical inspection of the infected goats

and the specimen procedure were approved out as the procedure described by (13). Dried scabs from the infected goats were collected and stored in freezer until testing via PCR.

### Molecular identification of Orf virus by PCR

Collected scabs from infected goats were homogenized by means of germ-free plasters and pestles within the utility of hygienic sand and physiological buffer saline to yield 20% tissue suspension and had achieved to be used in DNA extraction. DNA extraction was passed out by viral nucleic acid extraction kit (QIAGEN/Germany) from samples as according to manufacturer's protocol. The procedure used a specific primer at 408 pb of GIF gene (15), forward primer sequence is 5-GCTCTAGGAAAGATGGCGTG -3 and reverse primer sequence is 5-GTACTCCTGGCTGAAGAGCG -3. PCR procedure was accomplished according to the manufacturer's instruction. Thermal cycler was automated conferring to the following circumstances; 95°C for 5 mins as a first beginning step, tracked with 30 cycles of 95°C for 30s; 65°C for 30s, 72°C for 45s, and one ending cycle of 72°C for 7 mins. PCR harvests were run in the 2% agars gel and electrophoresed at 100 V for 60 mins, and DNA bands were visualized with ethidium bromide staining.

### Nucleotide sequencing besides phylogenetic analysis

The pure *GIF* gene PCR product samples were perpetrated to perform DNA sequencing by (Bioneer. Company, Korea - DNA sequencing system). Sequences were explored and firmed by Clustal W 2 system in the Meg-Align database of Laser-gene ((DNA/STAR Inc. Madison, USA). The sequences were associated with homologous sequences of reference strains from NCBI Gen Bank and phylogenetic diagram for GIF genes of ORFV were assembled using MEGA 6 software. The genetic detachments between sequences were considered and used for building of a neighbor joining tree for local ORFV B2L gene (16).

### Data analysis

The data obtained in this study were analyzed by IBM SPSS Statistical software version 22.0 and the statistical significance was set at  $P < 0.05$ .

## Results

### Clinical examination

Orf virus was detected in all crust samples that tested using GIF gene (Figure 2), however, the prevalence of orf in local goat was 10% (40/400). Clinical observation of infected goats was founded dry ulcerative and scabby characteristic lesions as thick wart-like multiple scratches on the oral fissures, lips and nostril part in goat were seen. No visible lesions were found in other locations. On the

other hand, adults showed mild fever 40-40.5°C, respiratory and heart rates were normal in most examined cases. In kids, the acute form was domain which includes fever ranged between 41 to 42°C, anorexia, depression, serous to mucopurulent nasal discharge, conjunctivitis, abnormal respiratory sounds (wheezing) with difficult inspiration dyspnea. Respiratory rate was increased and heart rate also was higher than normal, and the oral lesions made most infected kids unable to suck and /or graze feed and death were noticed in two cases in kids, mortality rate 0.5% (2/400). In table 1, there was a scientific important connotation among the orf prevalence and age, 70% (28/40) of kids higher than adult 30% (12/40), there was a higher disease occurrence in females 65% (26/40) than in males 35% (14/40).

Table 1: The effect of gender and age of goats on prevalence rate of orf using PCR

Gender (n)	Kids		Adults		Total	
	+ve	%	+ve	%	+ve	%
Female (26)	18	64.2	8	66.6	26	65 A
Male (14)	10	35.7	4	33.3	14	35 B
Total (40)	28	70 a	12	30 b		

**Molecular detection**

Detection of the virus using PCR was conducted. The results illustrated the presence of the virus in all samples regarding to the GIF gene (Figure 2).

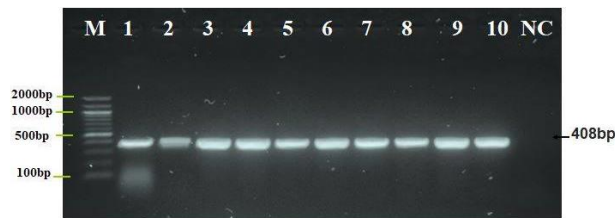


Figure 2: Agarose gels electrophoresis portrait that demonstrates the PCR product exploration of GIF gene in ORFV positive isolates. M: marker 100-2000 bp, lane 1-10, confident ORFV at 408 bp PCR product.

**Phylogenetic analysis**

Two amplicons gotten by PCR were sent out for sequencing to be identified and matched up with local two Iraqi and eight global strain references. All sequences were placed in GenBank as shown in (Figure 3).

Built on analysis of the sequence of the GIF gene, the Iraqi goat orf virus strain exhibited 99.05% of character at the nucleotide range with the Iraqi sheep Orf virus KJ697772.1 and the second Iraqi goat ORFV strain display 99.34% identity at the nucleotide level with the other strain of Iraqi sheep ORFV KJ653446.1 as in table 2.

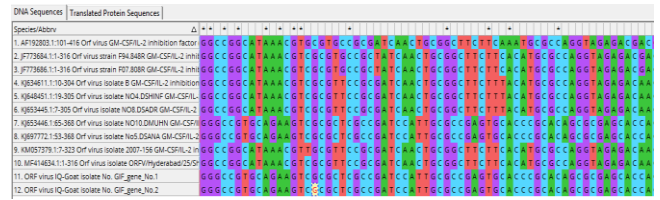

Figure 3: Multiple sequence arrangement analysis of GIF gene in local ORFV IQ-Goat isolate and NCBI-Genbank in local ORFV IQ-Goat isolate. The multiple alignment analysis was created using ClustalW alignment implement in MEGA 6.0 version. That show the nucleotide alignment likeness as (\*) with substitution mutations in GIF gene.

Table 2: BLAST submitted ORFV IQ-Goat isolates

Isolate No.	NCBI-BLAST Homology Sequence identity			
	Identical <i>F. succisae</i> isolate	Genbank Accession No.	Country	%
Isolate No.1	No5.DSA NA GM-CSF/IL-2	KJ697772.1	Iraq	99.05
Isolate No.2	No10.DM UHN GM-CSF/	KJ653446.1	Iraq	99.34

The local isolates presented only a 0.66-0.95% variance from the Iraqi Orf references virus strains detected in 2015 (Figure 4). Phylogenetics analysis based on the partial GIF genes (Figure 4) indicated that Iraqi strains were closely related to the Iraqi types; with which it has progressed from a communal progenitor.



Figure 4: Phylogenetic tree analysis based on GIF gene partial sequence in local ORFV IQ-Goat isolate.1 isolates that was run for genetic relationship documentation. The phylogenetic map was made by unweight Pair Group way with Arithmetic Mean (UPGMA tree) in MEGA 6.0 version. The native ORFV IQ-Goat Isolate No. 1- No.2 were indicated closed related to NCBI-BLAST ORFV isolate No5.DSANA GM-CSF/IL-2 and ORFV isolate NO10.DMUHN GM-CSF KJ697772.1 and KJ653446.1 respectively at total genetic changes 0.0005-0.0015%.

## Discussion

The Overall prevalence rates of orf founded through this research were very much lesser likened to that of 60% in India, 60% in Ethiopia, 34.89% in China and closely to infection rates reported in Malaysia 14.4%, 13% in India (17). However, orf in local goat in Iraq was determined by PCR as Orf sickness have been described in numerous countries, such as China, Croatia, Italy and Taiwan. Clinically; propagative lesions were seen on the lips, muzzle, eye and everywhere the nostrils with sever clinical signs in kids than in adult, these answers were in treaty with those of (18) and matching with alike clinical symbols were stated by additional researches on spreadable ecthyma in goats and sheep.

The incidence of orf illness can be prejudiced by age and gender which was higher in kids and this finding is in agreement with (10) documented a higher orf infection in kids (70%) and Similarly, by (4), and the younger animals can be extremely infected (3). Controversially, (14) specified that in adult goats the clinical marks might be extra severe, while, (5) presented orf is independent age disease. Meanwhile, female gender had the highest orf incidence; this harmonizes with a preceding study by (5,12). However, unfit sample size by which bulk of the topics studied was female may donate to unreliable statement. In the meantime, earlier annotations exposed that orf contagion have not intolerant predispositions between gender (2,18). In adults the lesion is milder; it may be related to the previous infection when they were kids.

The mortality rate was 0.5%, that closely to reports the small mortality rate of orf, extending from 0.8% to 24.7% (18). Meanwhile, (17) observed no mortality in orf unless the sick animal develops secondary bacterial or mycotic infection or being neglected without nursing.

Orf is a debilitating disease not fatal, but it can be fetal if kids are prohibited from suckling or exposure to minor bacterial or fungal infections. Increasing amount of ORFV contagion in goats may be owed to lack of vaccination policy, mixing rearing system is including sheep, goat and cattle together, continuous moving infected animals between different feeding area which spread ORFV, this observation is in agreement with (19). The two isolates of Iraqi infection were clustered in a single bunch, indicating great level of genetic homology between the isolates. BLAST searches in Gen-Bank revealed these sequences of two Iraqi orf isolates to be 99.05%-99.34% matching to Iraqi ORFV strains that previously submitted in Gen-Bank at 2015, and they also were acquiesced to the NCBI Gen Bank database and allocated the accession numbers KP869116-KP869120. Homology investigates displayed that the five strains bunch together, with related nucleotide variation. This phylogenetic characterization specifies that the *GIF* gene is an extremely well-maintained section in ORFV. The phylogenetic analysis displayed that these two

orf goat viruses are strictly related antigenetic. Furthermore, homology based phylogenetic inquiry presented that the goat ORFV *GIF* gene is closely similar to that of Iraqi orf sheep, this indicates that ORFV contagion is endemic in small ruminants in Iraq, with incessant hazard of transmission and outbreak occurrence.

This result; like in (20); indicates that ORFV of dairy goats might transmitted from infected sheep because in rural areas of Iraq small ruminants are farmed together with frequent contacts between them without quarantine, the infected animals are aggregate at night all in narrow closed pens especially in winter months. Like other diseases detected by (21-24) it is highly regarded that orf is an important disease because of its effect on the animal's health and the economic loses made during the disease onset and the treatment.

## Conclusions

We concluded that the Iraqi ORFV infecting the local goat was closely related phylogenetically to Iraqi ORFV strains infecting sheep. The age and gender have a significant effect on orf occurrence.

## Acknowledgements

We would like to thank the labors of owners and all the work of molecular diagnostic lab for their support and taking part in case and facts assortment of this research.

## Conflict of interests

The writers don't have any fight of interest concerning the contented of this research.

## References

1. Hosamani M, Scagliarini A, Bhanuprakash V. Orf: an update on current research and future perspectives. *Expert Rev Anti Infect Ther.* 2009;7: 879-893. DOI: [10.1586/eri.09.64](https://doi.org/10.1586/eri.09.64)
2. Spyrou VG. Orf virus infection in sheep and goats. *Vet Microbiol.* 2015;181:178-182. DOI: [10.1016/j.vetmic.2015.08.010](https://doi.org/10.1016/j.vetmic.2015.08.010)
3. Lojkić I, Zeljko CZ, Beck A. Phylogenetic analysis of Croatian orf viruses isolated from sheep and goats. *Virology.* 2010;7(314):2-7. DOI: [10.1186/1743-422X-7-314](https://doi.org/10.1186/1743-422X-7-314)
4. Gao Y, Zhao Y, Liu J. Orf in goats in China: prevalence and risk factors. *J Agric Sci Technol.* 2016;6:116-23.12. DOI: [10.17265/2161-6256/2016.02.005](https://doi.org/10.17265/2161-6256/2016.02.005)
5. Bala JA, Balakrishnan KN, Abdullah AA. Sero-epidemiology of contagious ecthyma based on detection of IgG antibody in selected sheep and goats farms in Malaysia. *Advan Anim Vet Sci.* 2018;6(5):219. DOI: [10.17582/journal.aavs/2018/6.5.219.226](https://doi.org/10.17582/journal.aavs/2018/6.5.219.226)
6. Oem JK, Roh IS, Lee KH. Phylogenetic analysis and characterization of Korean orf virus from dairy goats: Case report. *Virology.* 2009;6:167. DOI: [10.1186/1743-422X-6-167](https://doi.org/10.1186/1743-422X-6-167)
7. Jaiswal M, Nazeer M, Varshney R. Clinical management of contagious ecthyma in goats - a case report. *Inter J Curr Microbiol App Sci.* 2019;8(2):879-883. DOI: [10.20546/ijcmas.2019.802.099](https://doi.org/10.20546/ijcmas.2019.802.099)



8. Zeedan GG, Hassanain MA, Shaapan RM. Isolation of parapoxviruses from skin lesion of man and animals in middle Egypt. Global Vet. 2014;12:19-25. DOI: [10.5829/idosi.gv.2014.12.01.81156](https://doi.org/10.5829/idosi.gv.2014.12.01.81156)
9. Maganga GD, Relmy A, Bakkali-Kassimi L. Molecular characterization of Orf virus in goats in Gabon, Central Africa. Virol J. 2016;12:1-5. DOI: [10.1186/s12985-016-0535-1](https://doi.org/10.1186/s12985-016-0535-1)
10. Catroxo MB, Martins AM, Souza F. Detection of Parapoxvirus in goats during contagious ecthyma outbreak in Ceará State, Brazil by transmission electron microscopy techniques. IJOEAR. 2017;3:2454-1850. [\[available at\]](#)
11. Radostits OM, Gay C, Hinchcliff KW, Constable PD. A textbook of the diseases of cattle, horses, sheep, pigs and goats. 10<sup>th</sup> ed. London: Saunders Elsevier; 2010. 1418-1420 p.
12. Nandi S, De UK, Chowdhury S. Current status of contagious ecthyma of Orf disease in goat and sheep: Global perspective. Small Ruminant Res. 2011;96:73-82. DOI: [10.1016/j.smallrumres.2010.11.018](https://doi.org/10.1016/j.smallrumres.2010.11.018)
13. Kottaridi C, Nomikou K, Teodori L. Phylogenetic correlation of Greek and Italian orf virus isolates based on VIR gene. Vet Microbiol. 2006;116(4):310-6. DOI: [10.1016/j.vetmic.2006.04.020](https://doi.org/10.1016/j.vetmic.2006.04.020)
14. Gallina L, Scagliarini L, McInnes CJ. Parapoxvirus in goats: Experimental infection and genomic analysis. Vet Res Commun. 2008;32: S203-S205. DOI: [10.1007/s11259-008-9158-3](https://doi.org/10.1007/s11259-008-9158-3)
15. Damon I. Poxviridae and their replication. New York: Raven Press Ltd; 2007. 2079-2081 p.
16. Deane D, Ueda N, Wise LM. Conservation and variation of the parapoxvirus GM-CSF-inhibitory factor (GIF) proteins. J Gen Virol. 2009;90:970-977. DOI: [10.1099/vir.0.006692-0](https://doi.org/10.1099/vir.0.006692-0)
17. Babu TS, Rathnamma D, Shrikrishna I. Diagnosis of Orf virus infection in sheep and goat by virus isolation, polymerase chain reaction and sequencing. J Exper Biol Agric Sci. 2018;6(1):176-187. DOI: [10.18006/2018.6\(1\).176.187](https://doi.org/10.18006/2018.6(1).176.187)
18. Sadiq MA, Abba Y, Jesse FA. Severe persistent case of contagious Ecthyma (Orf) in goats. J Anim Hlth Product. 2017;5(1):24-8. DOI: [10.14737/journal.jahp/2017/5.1.24.28](https://doi.org/10.14737/journal.jahp/2017/5.1.24.28)
19. Pugh DG, Baird AN. Sheep and goat medicine. 1<sup>st</sup> ed. USA: Elsevier Ltd; 2002; 203-204.
20. Kaream SM. Study of some clinical and epidemiological Features and rapid detection of orf disease in sheep by molecular techniques [master's thesis]. Al-Qadisiyah: College of Veterinary Medicine, Al-Qadisiyah University, Iraq; 2016.
21. Mansour KA, Hassan HN, Muthanna HH. Phylogenetic tree analysis study of bovine papillomaviruses type 1 based on L1 gene in Al-Qadisiyah governorate, Iraq. Iraqi J Vet Sci. 2019;33(1):151-155. DOI: [10.33899/ijvs.2019.125535.1057](https://doi.org/10.33899/ijvs.2019.125535.1057)
22. Bahzad M. Detection on ectoparasites on small ruminants and their impact on the tanning industry in Sulaimani province Iraqi J Vet Sci. 2019;33(2):303-309. DOI: [10.33899/ijvs.2019.162995](https://doi.org/10.33899/ijvs.2019.162995)
23. Abdul Aziz JM, Salih AH, Hawre KF. Molecular diagnosis and genetic relationship of foot and mouth disease virus serotype Asia1/Basne/Sul/2015. Iraqi J Vet Sci. 2019;33(1):67-73. DOI: [10.33899/ijvs.2019.125519.1041](https://doi.org/10.33899/ijvs.2019.125519.1041)
24. Muhammed SW, Hasso SA, Abdulla FA. Serological diagnosis of FMD in sheep in Basra by ELISA test. Iraqi J Vet Sci. 2013;27(2):79-84. DOI: [10.33899/ijvs.2013.82785](https://doi.org/10.33899/ijvs.2013.82785)

## مرض الاورف في الماعز المحلي، دراسة سريرية و تطورية في محافظة القادسية في العراق

خليفة علي منصور، مثنى هادي حسين، أسعد جاسم عبد و قاسم حليم كشاش

فرع الطب الباطني، كلية الطب البيطري، جامعة القادسية، الديوانية، العراق

### الخلاصة

هدفت هذه الدراسة إلى تشخيص فيروس الأورف من الماعز المصابة في محافظة القادسية في العراق باستخدام تفاعل البلمرة المتسلسل وبناء شجرة النشوء والتطور. تم إجراء الفحص السريري على ٤٠٠ ماعز من قطعان مختلفة وتم جمع قشور جلدية من أربعين ماعز مصابة. وتم إخضاع جميع القشور لفحص تفاعل السلسلة المتبلعمة وتحليل النشوء والتطور والذي يتضمن وجود جين GIF العامل المثبط GM-CSF وهو الجين المميز للفايروس. كانت الأفة الجلدية التكاثرية النموذجية للنتائج بواسطة تفاعل البلمرة المتسلسل ١٠٪ مع معدلات وفيات منخفضة وتباين كبير في أهمية الإصابة مع العمر والجنس. تم إرسال اثنين من أمبليكون الموجبين لفحص التسلسل الجزيئي القائم على الجينات وتحليل النشوء والتطور. أظهرت للتسلسلات المتعددة قربها مع عزلتين عراقيتين عالميتين للفايروس. لم تكثف هذه الدراسة بالكشف عن التسلسلات الجديدة من عزلات الفايروس، ولكنها وفرت أيضا بيانات مهمة حول انتقال فايروس أورف الأغنام المحلي إلى الماعز المحلي أثناء التربية والرعي وان تفشي المرض في المجترات الصغيرة في العراق قد يكون متوقعا.