

Histopathological effect of fluoxetine drug on the brain of pregnant mice and their embryos

B.A. Salah

Department of Biology, College of Education for Pure Science, University of Mosul, Mosul, Iraq
Email: mohamedbaidaa5@gmail.com

(Received January 29, 2019; Accepted February 26, 2019)

Abstract

The present study was designed to identify the histopathological effect of fluoxetine (fluoxetine hydrochloride) on the pregnant mice brain and their fetuses as well as recording weight changes at doses of 60 and 80 mg/kg of body weight which were administrated to the pregnant mice from the 7th up to the 18th day of pregnancy and once a day. The results showed histopathological lesions in the adult pregnant mice brain at the dose of 60 mg/kg. induced massive necrotic area of neurons in the cerebral cortex, necrosis of the molecular layer cells while the dose of 80 mg/kg the changes include vasogenic edema in the sub cortical area, severe degeneration and necrosis of the cortex. The lesions in cerebellum were more severe than recorded in the cerebrum. The results also showed the presence of many lesions in the fetus brain at the dose 60 mg/kg and they were degeneration, necrosis of many neurons in the cerebrum while at the dose of 80 mg/kg. There were increase of degeneration and necrosis in the cortical area of fetus brain. In conclusion, the use of fluoxetine in pregnant mice caused decrease in body weight and Histopathological changes in the brain of both of the mothers and their embryos, thus the use of antidepressant by pregnant woman can be harmful for the mothers and the fetus.

Keywords: Histopathology, Fluoxetine, Mice, Brain, Fetus

Available online at <http://www.vetmedmosul.com>, © 2020, College of Veterinary Medicine, University of Mosul.

This is an open access article under the CC BY 4.0 license (<http://creativecommons.org/licenses/by/4.0/>).

التأثيرات النسجية المرضية لعقار الفلوكستين على دماغ الفئران الحوامل وأجنحتها

بيداء عبد العزيز محمد صالح

قسم علوم الحياة، كلية التربية للعلوم الصرفة، جامعة الموصل، الموصل، العراق

الخلاصة

صممت الدراسة الحالية لتشخيص تأثير عقار الفلوكستين على دماغ الفئران الحوامل وأجنحتها وكذلك تسجيل التغيرات الوزنية باستخدام الجرعتين 60 و 80 ملغم/كغم من وزن الجسم والتي أعطيت للفئران الحوامل من اليوم السابع إلى اليوم الثامن عشر من الحمل ولمرة واحدة يوميا. أظهرت النتائج آفات نسجية مرضية في دماغ الفأر الحامل عند التركيز 60 ملغم/كغم من وزن الجسم وتمثلت بمنطقة تنخرية واسعة في عصبونات القشرة المخية، فضلا عن نخر الخلايا في الطبقة الجزيئية، أما عند التركيز 80 ملغم/كغم من وزن الجسم فتمثلت الآفات بأدمة وعائية ونخر في خلايا منطقة القشرة الدماغية وكانت الآفات المرضية في الدماغ كانت أكثر شدة مما سجلت في المخيخ. أظهرت النتائج العديد من الآفات في دماغ الأجنة عند التركيز 60 ملغم/كغم من وزن الجسم وتمثلت بتنكس ونخر العصبونات في الدماغ، أما عند التركيز 80 ملغم/كغم من وزن الجسم فقد أظهرت النتائج زيادة التنكس الخلوي ونخر في منطقة القشرة المخية. نستنتج أن استعمال عقار الفلوكستين في فترة الحمل للفئران يتسبب بتغيرات نسجية مرضية في دماغ الأم الحامل وأجنحتها عند تعاطيه بجرعات عالية وفقدان الوزن وعليه نستطيع أن نعد هذا العقار سام إذا استعمل خلال الحمل بجرعات عالية. ونستنتج بهذا أن إعطاء الفلوكستين للفئران يتسبب بتغيرات وزنية تمثلت بانخفاضها فضلا عن ظهور آفات نسجية مرضية في دماغ الفئران الحوامل وأجنحتها وبهذا فان استعمال الأم الحامل في الإنسان لمضادات الاكتئاب يكون مضر ومؤذي لها ولأجنحتها.

Introduction

Fluoxetine hydrochloride is used to treat a number of psychiatric conditions in humans and behavioral problems in animals (1), it is fluorinated methyl phenoxy derivate of phenylpropylamin, the drug also known by trade name as Prozac, fluoxetine antidepressant of serotonin reuptake inhibitor (SSRI) (2). Serotonin is a neurotransmitter which means it relays signals between cells in the brain (3). The drug ingested by the mouth usually once a day in the morning (4), this drug doesn't only used for the treatment of major and minor depression also used for relieve nausea, vomiting during early pregnancy (5,6). Pregnancy should be carefully evaluated given that it is a period during which woman go through many physical, hormonal and psychic changes which in turn influence the health of both mothers and their fetuses (7). These changes during pregnancy may result in serious emotional problems because fluoxetine and its metabolite norfluoxetine have been shown to cross placental barrier that may cause damage in the major organs of both mother and the fetus such as liver, kidney and other organs, it also may lead to increased extracellular serotonin levels and potentially neurodevelopmental changes in the fetus, it pass the blood brain barrier (8), the fluoxetine transferred from the mother to the fetus through blood plasma so it may spread in to entire the brain of the fetus (9), as well as it may lead to abortion if it used during second and third trimester so that the drug is able to produce a significant histopathological lesions in most vital body organs as well as malformations (10). That means drug can affect the fetus functional development and growth (11). Fluoxetine and its metabolite nor fluoxetine secreted in breast milk and data indicated that these compounds concentration are about 20 - 30 % concurrent maternal plasma drug concentration especially in the rats and these compounds are become at highest level in fetal brain (12). Experimental studies indicated that fluoxetine decrease antioxidant levels, induced oxidative stress and modulating it in different body organs specially the brain that deepened on the taken dose and treatment period (13,14), in the last few years using medications among them fluoxetine increase to treat all emotional and physical changes during pregnancy (15). So that the objective of the present study was to investigate the histopathological changes in the brain of the pregnant mice and their fetuses which treated with fluoxetine and to record the weight changes.

Materials and methods

Animals, housing and mating

The present study was carried on 60 pregnant mice weighting 30 ± 3 gm at age 60 ± 4 days for 3 months. At the time when the experiment started, the animals were

obtained from animal house of Mosul medicine college Mosul University, Mosul - Iraq. All animals housed in clean cages with ad libitum access to water and standard chewable food diet at room temperature 25 ± 1 °C and mice were kept under a natural light - dark cycle (9). For mating mature males were caged at the afternoon for overnight with females in a ratio of one male / two females / cage (16), at the next morning the presence of vaginal plug was considered as the first day of the pregnancy according to the (17), where they still undisturbed until the day 6th of gestation the females were transferred from the mating cages and divided into groups. Medication that was used in the present study is fluoxetine 20 mg capsules the production company is Bristol laboratories Ltd, United Kingdom.

Experimental design

The pregnant mice were divided in to three groups and each group consist of 20 pregnant mice (n=20). Group I: control group which administrated orally with 0.2 ml of distilled water from the day 7th until the day 18th of pregnancy. Group II: which administrated orally with 60mg/ kg from the day 7th until the day 18th of pregnancy. Group III: which administrated orally with 80mg/ kg of B.W. from the day 7th until the day 18th of pregnancy. The concentrations 60 mg and 80 mg / kg of the fluoxetine were prepared by dissolving each concentration in 5 ml of distilled water (stock solution) and the doses were given depending on the weight of the mice, it was taken from the stock solution according to the mice weight and the dose almost was between 1.5-2 ml which was given to the pregnant mice, the doses were freshly prepared every day, the doses that used in the present study had been chosen depending on the LD₅₀ of the fluoxetine which is 100mg /kg (18). The pregnant mice were weighted on the 7th and 18th day of gestation for once by using electronic sensitive balance, all weights were recorded and their rates were calculated for all groups to identify the effect of the drug in the weight between the control group and the treated groups as well as to determine the effect of the dose on the weight of the two groups which treated with concentrations 60 and 80 mg/kg.

Histopathological examination

For Histopathological examination, the animals were sacrificed, dissected after 12 hours from the last dose which was in the 18th day of pregnancy, the brain of both mothers and their embryos were isolated and rinsed with normal saline solution, the samples were fixed in formalin 10 % for 48 hours (19), after fixation the brain tissue (brains of the mothers and fetus) were washed with distilled water the samples were treated by routine histological process of paraffin embedded tissue and stained with Delafield's hematoxylin & eosin, sections were mounted with D.P.X.

and examined using optical microscope (20). For photographed a digital camera was used of the type Sony, Cybershot, Japan.

Results

Microscopical observations of the brain of adult pregnant mice

Microscopic examination of control cerebrum, which is one of brain parts revealed normal cerebral tissue composed of glial cells and neurons (Figure 1). Sections from the brain of second group were show sever necrotic area of neurons in cerebral cortical area (Figure 2). In third group the sections of brain were show vasogenic edema (Figure 3). Also, there was sever degeneration and necrosis in the brain cortex which revealing extensive destruction of the cerebral tissue (Figure 4).

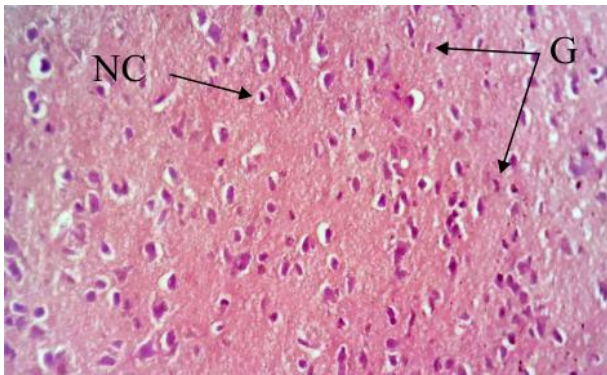


Figure 1: Histological section in a female brain of adult pregnant mice *Mus musculus* (control), composed of glial cells (G) and neurons cells (NC). H&E, 100x.

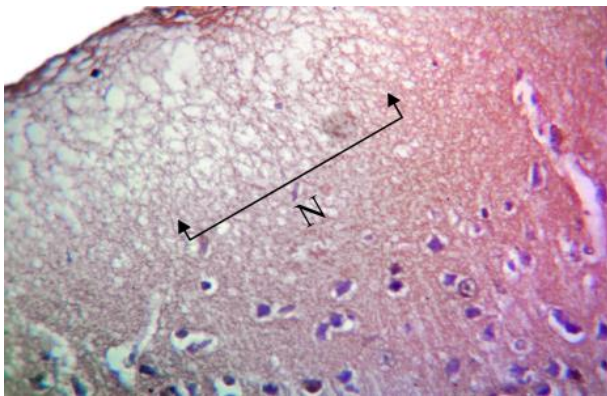


Figure 2: Histological section in a female brain of adult pregnant mice *Mus musculus* treated with fluoxetine drug at a dose of 60 mg/ kg of B.W. from the 7th day until the 18th day of gestation showing necrotic area (N) in the cerebral cortex. H&E, 400x.

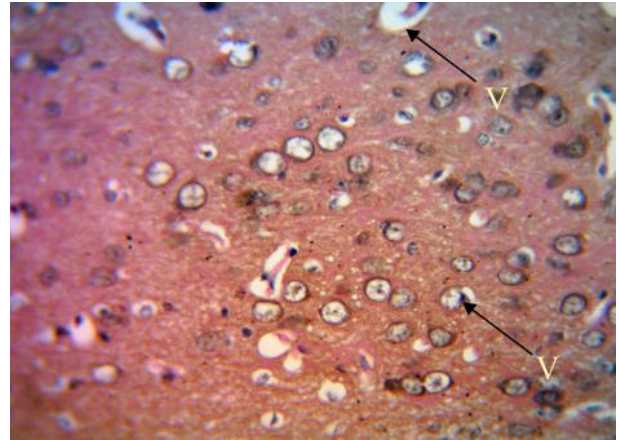


Figure 3: Histological section in a female brain of adult pregnant mice *Mus musculus* treated with fluoxetine drug at a dose of 80 mg/ kg from the 7th day until the 18th day of gestation showing: vasogenic edema (V). H&E, 400x.

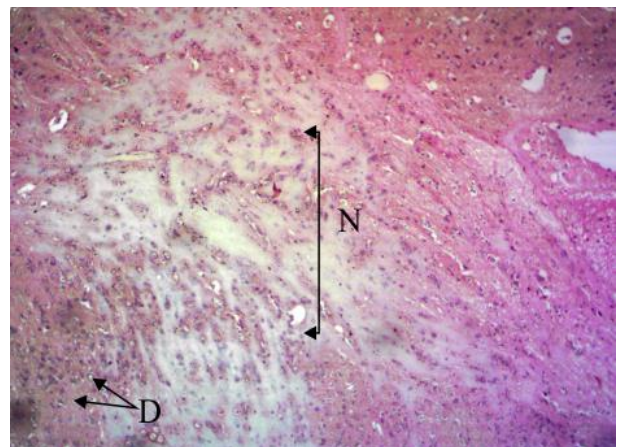


Figure 4: Histological section in a female brain of adult pregnant mice *Mus musculus* treated with fluoxetine drug at a dose of 80 mg/ kg of B.W. from the 7th day until the 18th day of gestation showing: degeneration (D) and necrosis (N) in the brain cortex. H&E, 400x.

Weight Changes

Adult pregnant mice weight was measured on the 7th and 18th day of gestation for control group and both groups which treated with the doses 60 and 80 mg/kg that used in the present study. The results showed that there was a marked decrease in body weight in all treated groups when compared with the control group. As well as there was more decrease in pregnant mice weight which treated with the dose of 80mg/kg of fluoxetine compared to the pregnant mice group which treated with the dose of 60 mg/kg of the same drug (Table 1).

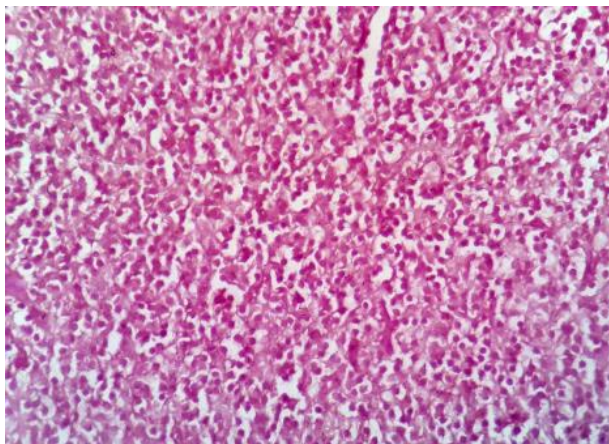


Figure 5: Histological section in a fetus brain of pregnant mice *Mus musculus* (control) showing: primitive normal tissue in the cerebrum. H&E, 400x.

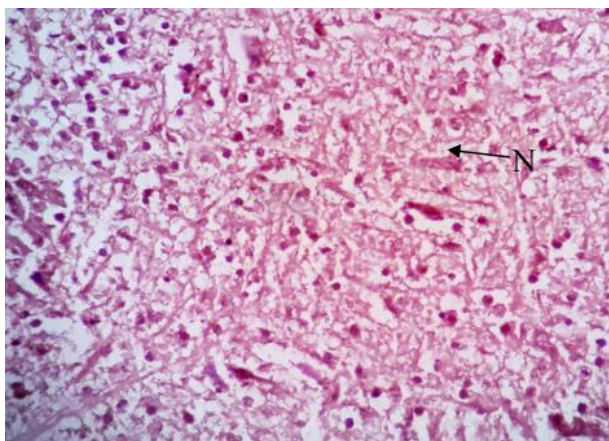


Figure 6: Histological section in a fetus brain of pregnant mice *Mus musculus* treated with fluoxetine drug at a dose of 60 mg/kg from the day 7th until the day 18th of pregnancy showing: necrosis (N) of many neurons in the cerebrum tissue. H&E, 400x.

Table 1: The effect of different dose of fluoxetine on weight of pregnant mice

	Weight (g) (Mean ± SE)	
	7 days	18 days
Control	32.14 ± 1.04	33.12 ± 1.27
60 mg/kg	30.98 ± 1.19	29.96 ± 1.01
80 mg/kg	30.56 ± 0.98	30.01 ± 1.11

Discussion

The histopathological findings of the present study in the pregnant mice brain showed satisfactory tissue lesions

when treated with fluoxetine at the doses 60 and 80 mg /kg from the 7th up to 18th days of pregnancy showed clear tissue degeneration and necrosis of the brain tissue, that were consisted with what were indicated by (21) when they treated mice with fluoxetine added to their dietary at the dose of 10 mg/kg for 24 months the drug caused histopathological changes in the central nervous system of the mice, while the results were not agreed with what were indicated by (22). The results also agree with what (23) referred to when they treated adult mice with fluoxetine for 12 weeks the drug cause decrease in the neurogenesis of the subventricular of the brain. The results also consisted with what (24) indicated when they treated rats with fluoxetine with the dose of 10 mg/kg for 1 month added in the drinking water, the treatment showed that there was abnormality presence like necrotic dead neuronal and non-neuronal cells in the brain cortex. The results agreed with what (25) indicated that fluoxetine stimulate changes in the mice brain. The lesions that occur in the present study maybe due to that fluoxetine decrease antioxidant levels and increase oxidant levels by elevating superoxide anion levels and induced oxidative stress, all these consequences may be cause of neuronal damage of the adult brain (13,26) and long-term exposure to the fluoxetine may cause brain tissue damage (27)

As well as the results of the microscopic examination of the mice fetal brain which administered orally with fluoxetine at the doses of 60 and 80 mg/kg from the 7th up the 18th days of pregnancy showed many lesions represented with degeneration and necrosis of the neurons which were agreed with what were indicated by (28), thus suggesting that the use of antidepressant by pregnant woman can induce alternation in their neural development (19).The results also agreed with what (19) indicated when they injected the mice with 10 mg/kg of fluoxetine intraperitoneally in the days 9th, 10th, 11th of pregnancy the drug caused nervous tissue degeneration, decreased in the neuroglial tissue and wide spaces between neurons. The present results were similar to what (29) referred to when they gave fluoxetine orally to the pregnant rats in the days 1st, 4th, 8th, 12th, 18th of pregnancy that the brain contained moderate the levels of radioactivity so that the drug can cause damage of the nerve cells in the fetal brain. The lesions that occur in the present study may be due to the, fluoxetine was capable of differentially modulating oxidative stress in the brain (14), so monoaldehydes also increased, which is an index of lipid peroxidation, so that peroxidation activity was also increased this may lead to significant depletion of reduced glutathione so all this consequences can cause changes in the antioxidant levels of the brain which can cause brain tissue damage (30).

The results of the present study showed there was decrease in body weight in both treated groups with the doses 60 and 80 mg/kg compared to the control group. The

results of the present study consistent with what is indicated by (16) when they treated the pregnant mice with the fluoxetine at the doses of 0.05, 0.104, 0.204 mg/kg of B.W. from the 6th up to both 15th and 19th days of gestation as the drug caused reduction in pregnant mice weight. The results also were accordance with the findings of many investigators such as (31-33). While the results of the present study were not consistent with what was indicated by (34) when they injected the mice with the dose of 0.06 mg/kg for 30 days, the drug caused increase in body weight. The reduction of body weight in the present study may be due to that the fluoxetine is affecting intrauterine fetal development so the number of the uteri implantation and embryos were smaller compared to the normal state (35), or may be due to the, that serotonin and neuropeptide Y neurons in the hypothalamus respectively inhibit and stimulate food intake, fluoxetine not only inhibits various aspects of the activity of the neuropeptide Y but also, reduce neuropeptide Y release in the periventricular nucleus a major site of neuropeptide Y release which is highly sensitive to appetite stimulating actions of neuropeptide Y (36).

Conclusion

Using antidepressants in pregnancy specially during organogenesis has a negative effect on the brain structure of both mothers and embryos, so this may increase the risk of mental illness occurrences specially in the fetus later. Thus, caution should be taken when abusing this drug in critical periods of pregnancy and it should be taken under medical advice to reduce the occurrence of unwanted or dangerous side effects.

Acknowledgments

I would like to thank Dr. Nadwa S. M. Al-Azow for reading the histological slides. I offer her all thanks and respect. The author is very grateful to the University of Mosul, the college of Education for pure science/ department of Biology for their supporting, which helped to improve the quality of this work.

References

- Aboni S, Dijk R, Poggini S, Milior G, Perrotta M, Drenth T, Brunello N, Wolfer DP, Limatila C, Amrein I, Circulli F, Maggi L, Branchi I. Fluoxetine DOI: 10.1038/MP. 2015.142 effects on molecular, cellular and behavioural endophenotypes of depression are driven by living environments. *Mole Psychol.* 2017;22:552-561.
- Andrade S, Raebel M, Brown J, Jane K, Livingstone, J, Smith, Willy D, E, Staffa A, Platt R. Use of antidepressant medication during pregnancy: a multisite study. *Am J Obstet Gynecol.* 2008;e1991-e195. DOI: 10.1016/j.ajog.2007.07.036
- Baudry A, Mouillet S, Schneider B, Launay M, Kellermann O. MiR-16 target the serotonin transporter: A new facet for adaptive response to antidepressant. *Sci.* 2010;329(5998):1537-154. DOI: 10.1126/science.1193692
- Fournier, J.C.; Derubeis, J.R.; Hollon, S.D.; Dimidjani, S.; Amsterdam, J.D.; Shelton, R. C.; Fawcett, J. Antidepressant drug effects and depression severity: A Patient-Level Meta-Analysis. *J Am Med Assoc.* 2010;303(1):47-53.
- Cipriani A, Brambilla P, Furukawa T, Geddes J, Gregis M, Hotop M, Malvini L, Barbui C. Fluoxetine versus other types of pharmacotherapy for depression database. *Syst Rev.* 2005;9(2):81-85. DOI: 10.1002/14651858.CD004185.pub2
- Yohn N, Shifman A, Diethorn L, Bokka L, Ashamalla A, Samules A. Fluoxetine effects on behavior and adult hippocampal neurogenesis in female C57BL / 6J mice across the estrous cycle. *Rxiv.* 2018;4:1-25. doi: <https://doi.org/10.1101/368449>
- Zinga D, Phillips D, Born L. Postpartum depression: We know the risks, can it be prevented? *Rev Bras Psiquiatr.* 2005;27(2):56-64. <http://dx.doi.org/10.1590/S1516-44462005000600005>
- Libosa F, Oliveira E, Costa C, Venancio J, Moreira G. Behavioral evaluation of male and female mice pups exposed to fluoxetine during pregnancy and lactation. *Pharmacol.* 2007;80:49-56. DOI: 10.1159/000103097
- Olivier A, Valls A, VanHeesch F, Afrasiab A, Roeloes M, Jonkers M, Peeters J, Korte H, Dederen P, Kilian J, Martens J, Schubert D, Homberg R. Fluoxetine administration to pregnant rats increases anxiety-related behavior in the offspring. *Psychopharmacol.* 2011;11:217-414.
- Marcus M, Flynn A. Depression, antidepressant medication and functioning outcomes among pregnant women. *Inter J Gynaecol Obstet.* 2008;100(3):248-251. DOI: 10.1016/j.ijgo.2007.09.016
- Czeizel E, Puho H, Acs N, Banhidy F. Use of specified critical periods of different congenital abnormalities instead of the first trimester concept. *Birth Defects Res Clin Mol Teratol.* 2008;82(3):139-146. DOI: 10.1002/bdra.20431
- Goldstein J. Outcomes of fluoxetine exposed in pregnancy. *Am J Hum Genet.* 1990;47:136.
- Saker H, Abbas A, Elsamanoudy A, Ghoneim F. Effect of fluoxetine and resveratrol on testicular functions and oxidative stress in a rat model of chronic mild stress-induced depression. *J Physio Pharma.* 2015;66:515-527. PMID: 26348076
- Abdul-Salam E. The effect of antidepressant drugs on thioacetamide-induced oxidative stress. *Euro Rev Med Pharmacol Sci.* 2013;17:735-744. PMID: 23609356
- Ramos E, St-Andre M, Rey E, Oravichi D, Berard A. Duration of antidepressant use during pregnancy and risk of major congenital malformations. *Br J Psychiatr.* 2008;192(5):344-350. doi: 10.1192/bjp.bp.107.042523.
- Ali O, Sharf A, El menshawy M, Barkry A. Fluoxetine HCL induced intrauterine fetal growth retardation and skeletal malformation in pregnant mice. *Egy J Hosp Med.* 2002;6:63-79. DOI:10.12816/ejhm.2002.18857
- Ali O, El- Nahass E, Diamond O, Desouki G. Embryo toxic effect diabetes mellitus. *Al-Azhar Med J.* 1989;17(4):421-228. DOI: 10.1056/NEJM199309303291401
- Wang T, Byrnas P, Engleman A. Prozac (fluoxetine, Lilly 110140), the first selective serotonin uptake inhibitor and antidepressant drug: Twenty years since its first publication. *Life Sci.* 1995;57(5):411-441. DOI: 10.1016/0024-3205(95)00209-o
- Swerts S, Costa D, Estenes A, Borato S, Swerts O. Effects of fluoxetine and imipramine in rat fetuses treated during a critical gestational period: A macro and microscopic study. *Rev Bras Psiquiatr.* 2010;32(2):1-10. <http://dx.doi.org/10.1590/S1516-44462009005000015>
- A-Hajj A. Optical laboratory preparation. 1st ed. Amman: Dar Al-Massera; 2010. 40-44 p.
- Bendale A, Adams R, Hoffman P, Gries L, Morton M. Carcinogenicity studies of fluoxetine hydrochloride in rats and mice. *Cancer Res.* 1992;52(24):6931-5.

22. Holick A, Lee C, Hen R, Dulawa C. Behavioral effects of chronic fluoxetine in Balb/C mice do not require adult hippocampus neurogenesis or the serotonin 1A receptor. *Neuropsychopharmacol.* 2008;33:406-417.
23. Ohira K, Miykawa T. Chronic treatment with fluoxetine for more than 6 weeks decreases neurogenesis in the subventricular zone of adult mice. *Mol Brain.* 2011;4:10. doi: 10.1186/1756-6606-4-10
24. Rasul H, Mohamood S, Hamad H, Hassan H. Histological changes of the liver, kidney and brain in uninephrectomized male rats exposed to fluoxetine. *ZIPAS.* 2016;28(6):106-121.
25. Marlatt, M. ; Lucassen ,P. ; Praag ,H. (2010). Comparison of neurogenic effects of fluoxetine, duloxetine and running in mice. *Brain Res.*1341:93-99. doi: 10.1016/j.brainres.2010.03.086
26. Chen H, Panday N, Dwivedi Y. Hippocampal cell proliferation regulation by repeated stress and antidepressants. *Neuroreport.* 2006;17:863-867. DOI: 10.1097/01.wnr.0000221827.03222.70
27. Kroeze Y, Peeters D, Bouille F, Avanden H, Bokhoven V, Zhou H, Homberg R. Long- term consequences of chronic fluoxetine exposure on the expression of myelination-related genes in the rat hippocampus. *Psychiatry.* 2015;6(4):e779. doi: 10.1038/tp.2015.145.
28. Cabrera- vera M, Battaglia G. Delayed decrease in brain 5-hydroxytryptamine 2A/ 2C receptor density and function in male progeny following prenatal fluoxetine. *J Pharmacol Exp Ther.* 1994;209:637-645.
29. Pohland C, Koons R. Placental transfer and fetal distribution of fluoxetine in the rat. *Toxicol Appl Pharmacol.* 1989;98(2):198-205. DOI: 10.1016/0041-008x(89)90225-1
30. Gutterigae C. Lipid peroxidation and antioxidants as biomarkers of tissue damage. *Clinic Chem.* 1995;41:1819-1828.
31. Altemus M, Glowa R, Galliven E, Leong M, Murphy L. Effects of serotonergic agent on food restriction induced hyperactivity. *Pharmacol Biochem Behav.* 1996;53(1):123-131.
32. Curzan G, Gibson L, Oluoyomi O. Appetite suppression by commonly used drugs depends on 5-HT receptors but not on 5HT availability. *Pharmacol Sci.* 1997;18(1):21-25.
33. Vorhess V, Acuff-Smith K D, Schilling A. A developmental neurotoxicity evaluation of the effects of prenatal exposure to fluoxetine in rats. *Fundam App Toxicol.* 1994;23(2):194-205.
34. Ali M, Hakami A. Comparative studies on the effect of prozac drug and barely grains on the skeletal muscles of mice: Behavioral and histological studies. *J Appl Pharm Sci.* 2012;2(03):45-51.
35. Eugenia P, Vari E, Maria D. Fluoxetine effect on gestation and fetal development. *Acta Med Marisiensis.* 2014;60(4):157-159. DOI: <https://doi.org/10.2478/amma-2014-0034>
36. Dryden S, Frankish M, Wang Q, Pickavance L, Williams G. The serotonergic agent fluoxetine reduces neuropeptide Y levels and neuropeptide Y secretion in the hypothalamus of lean and obese rats. *Neurosci.* 1996;72(2):557-566.